

A Morphometric Study On Measurement Of Depth Of Acetabulum

Mahato PK¹, Tiwari RK², Singh PK³

1. Associate Professor, Department of Anatomy, Index Medical College Hospital and Research Centre, Indore, MP
2. Research Scholar, Department of Anatomy, Index Medical College Hospital and Research Centre, Indore, MP
3. Assistant Professor, Department of Radiology, GMC Ajamgarh, UP

Corresponding Author:

Tiwari RK, Research Scholar, Department of Anatomy, Index Medical College Hospital and Research Centre, Indore, MP,
kr.rakeshtiwari97@gmail.com
DOI: 10.47750/pnr.2022.13.S08.643

Abstract

Introduction: The acetabulum is also home to the acetabular fossa, an attachment site for the ligamentum teres, a triangular, somewhat flattened band implanted by its apex into the antero-superior part of the fovea capitis femoris. The notch is converted into a foramen by the transverse acetabular ligament; through the foramen nutrient vessels and nerves enter the joint. **Materials and Methods:** This is a prospective, descriptive, cross sectional and observational study conducted at Department of Anatomy and Radiology, Government Medical College, Ajamgrah and Department of Anatomy and Radiology, Index Medical College, Indore from January 2020 December 2022. Study group divided into 3 groups: **Group A:** 18-35 years, **Group B:** 36-55 years and **Group C:** 56-75 years. **Result:** It is defined as the angle between the line connecting the lateral edge of the acetabular roof touching the lower iliac tip of acetabular surface and a line parallel to the pelvic tear drop. The angle between the centre line of both femoral heads and the line from centre towards the anterior margin of acetabulum. The angle between the centre line of both femoral heads and the line from centre towards the posterior margin of acetabulum. **CONCLUSION:** The depth studied on acetabulum in the present study showed statistically significant differences between males and females. Studies based on depth of acetabulum are relatively few in the literature, hence the findings of the present study can provide a guideline for further studies on acetabulum. Considering that total hip replacement is a common surgery performed now a day, awareness of the dimensions of the acetabulum is of immense importance to the orthopaedic surgeons.

Keywords: Morphometric, Acetabulum, Acetabular, Ligamentum

Introduction

The acetabulum is also home to the acetabular fossa, an attachment site for the ligamentum teres, a triangular, somewhat flattened band implanted by its apex into the antero-superior part of the fovea capitis femoris. The notch is converted into a foramen by the transverse acetabular ligament; through the foramen nutrient vessels and nerves enter the joint. ^[1] This is what holds the head of the femur securely in the acetabulum. The well-fitting surfaces of the femoral head and acetabulum, which face each other, are lined with a layer of slippery tissue called articular cartilage, which is lubricated by a thin film of synovial fluid. Friction inside a normal hip is less than one-tenth that of ice gliding on ice. ^[2] The acetabular branch of the obturator artery supplies the acetabulum through the acetabular notch. The pubic branches supply the pelvic surface of the acetabulum. Deep branches of the superior gluteal artery supply the superior region and the inferior gluteal artery supplies the postero-inferior region. ^[3]

The acetabulum functions as the socket that accepts the rounded head of the femur. Together the acetabulum and the femoral head form the hip (coxal) joint. In male acetabulum is large and faces laterally and in female it is small and faces anteriorly. ^[4] The hip joint socket, the acetabulum ('vinegar cup'), is a concave hemisphere whose axis is not strictly horizontal but is directed also downwards and slightly backwards along the axis of the femoral neck. Its inferior margin is lacking, so the vinegar would run out of the cup. ^[5] The margins of this acetabular notch, curved in outline, are lined with hyaline cartilage, which continues as a wide band inside

the concave surface of the acetabulum. It is widest above, opposite the notch. This wide upper part of the articular surface is the weight bearing area, lying like a cap over the femoral head. [6]

The acetabular articular surface is deficient inferiorly opposite the acetabular notch and covered by articular cartilage, which is thickest where the surface is broadest. The acetabular fossa within it is devoid of cartilage but contains fibroelastic fat largely covered by synovial membrane. Acetabular depth is increased by the acetabular labrum, a fibrocartilaginous rim attached to the acetabular margin. This deepens the cup and bridges the acetabular notch as the transverse acetabular ligament. [7]

Materials and Methods

This is a prospective, descriptive, cross sectional and observational study conducted at Department of Anatomy and Radiology, Government Medical College, Ajamgrah and Department of Anatomy and Radiology, Index Medical College, Indore from January 2020 December 2023.

Inclusion criteria:

- Age > 18 years of either gender will be included.
- Persons willing to give consent.

Exclusion criteria

- Patients with hip pain on presentation will be excluded.
- Persons not willing to give consent.
- Pregnant women, those who experienced previous femoral injury, wearing implant or prosthesis.

Study group divided into 3 groups:

Group A: 18-35 years

Group B: 36-55 years

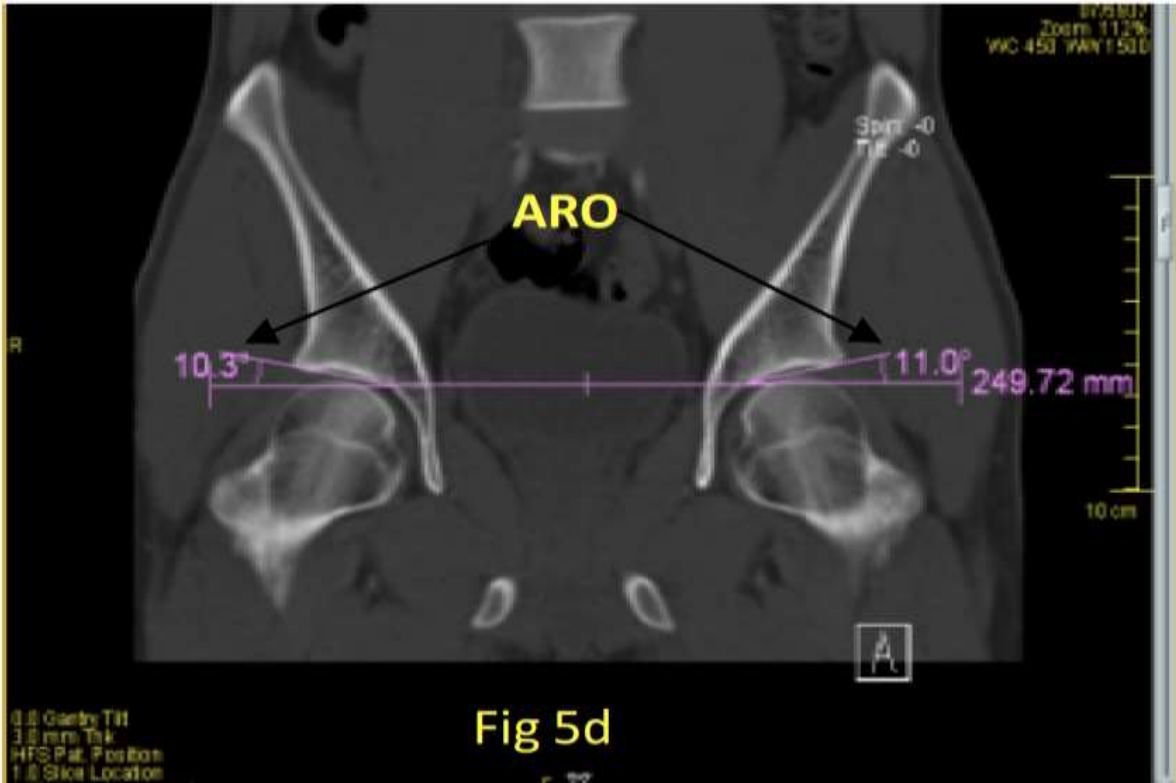
Group C: 56-75 years

Acetabular images will be acquired using CT scanner (Somatom, Volume Zoom, Siemens) at 3.0 mm thickness and 12.0 mm table feed per rotation. The four row multi slices CT scanner will be conducted using 120 kV and 90 mAs with recon increment will be set to 1.5 and 1.25 mm collimation. Subjects will be asked to lay down at supine position with their feet stabilized using the specially designed wood jig to standardize the position of feet during image acquisition.

The following data will be collected before the study: patient's age, gender, weight and height. The parameters involved will be

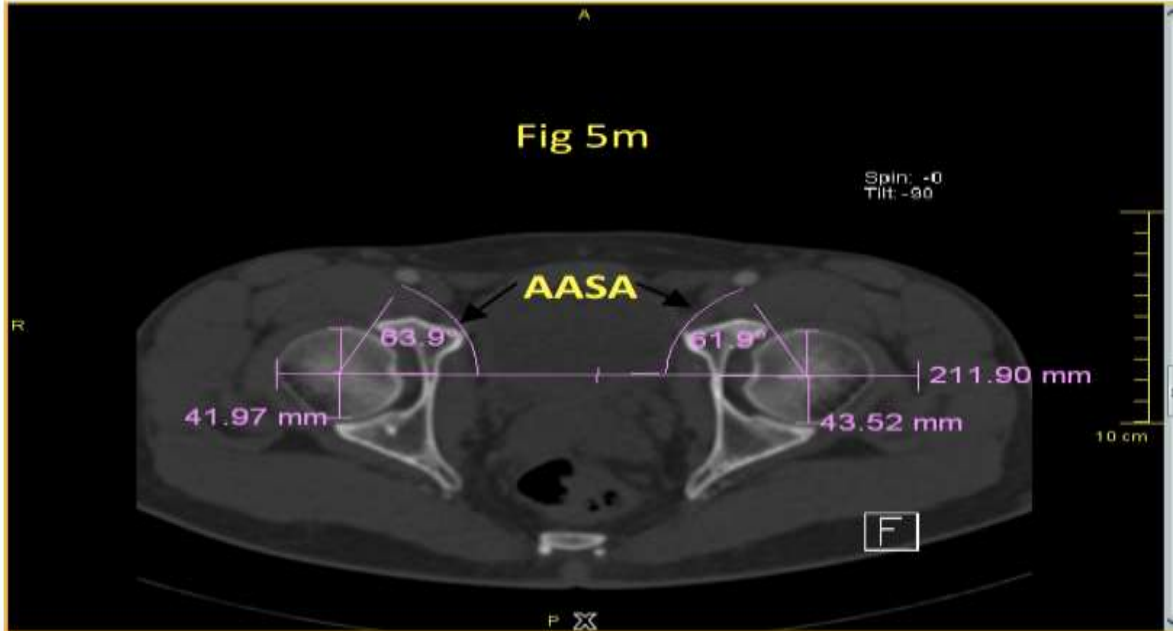
1) ACETABULAR ROOF OBLIQUITY:

It is defined as the angle between the line connecting the lateral edge of the acetabular roof touching the lower iliac tip of acetabular surface and a line parallel to the pelvic tear drop. (Fig 5d)



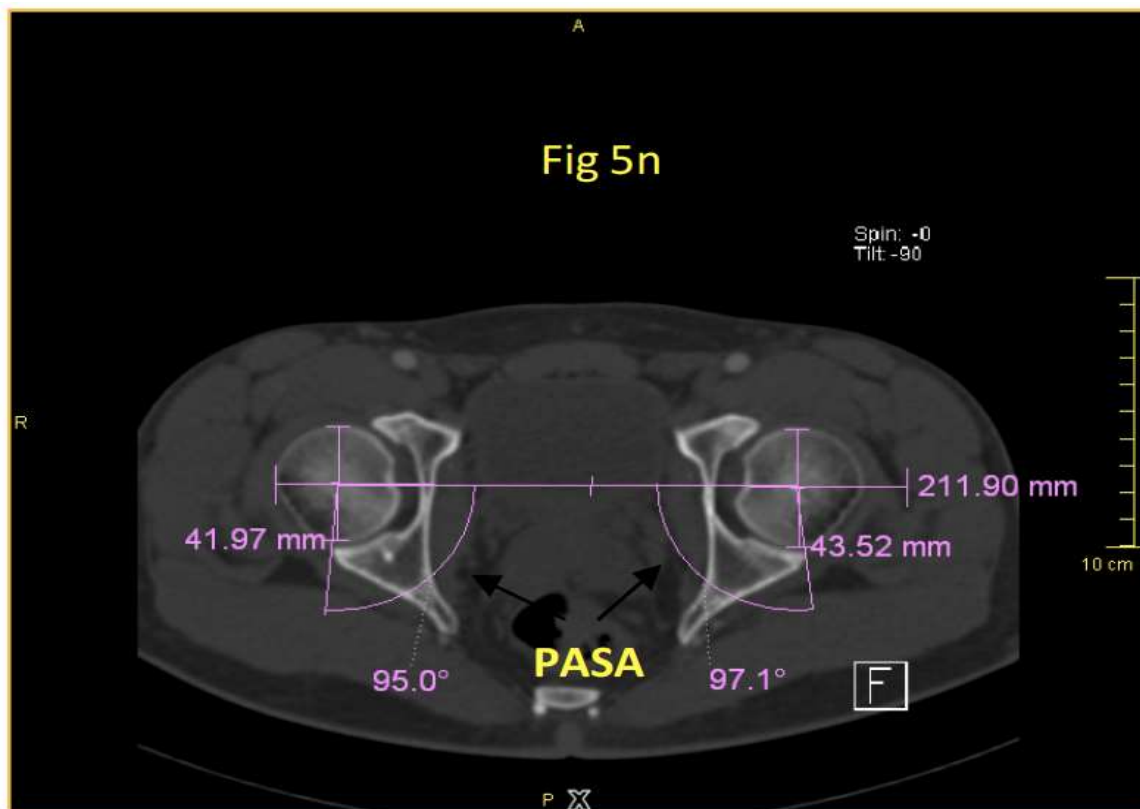
2) ANTERIOR ACETABULAR SECTOR ANGLE:

The angle between the centre line of both femoral heads and the line from centre towards the anterior margin of acetabulum. (Fig 5m)



3) POSTERIOR ACETABULAR SECTOR ANGLE:

The angle between the centre line of both femoral heads and the line from centre towards the posterior margin of acetabulum. (Fig 5n)



Result:

In our study total 154 subjects were enrolled. This sample was divided by gender with mean, Standard deviation and range value.

Table 1: Distribution of Gender and age

Gender	N	Mean (Year)	Standard deviation	Minimum	Maximum
Male	92 (60%)	31.23	4.24	19	50
Female	62 (40%)	29.42	3.14	19	40
Total	154 (100%)				

In our study male was 92 (60%) and female was 62 (40%).

Table 2: Distribution of weight

Weight (kg)	Mean	Standard deviation	Minimum	Maximum
Male	73.36	7.53	57	112
Female	57.53	5.36	40	86

Table 3: Distribution of height

Height (cm)	Mean	Standard deviation	Minimum	Maximum
Male	181.23	12.73	159	195
Female	163.68	11.59	139	163

Table 4: Distribution of BMI

BMI (kgm ²)	Mean	Standard deviation	Minimum	Maximum
Male	24.64	3.69	17	39
Female	21.38	2.96	15	37

Table 5: Acetabular morphometric measurement-Anterior acetabular sector angle (AASA)

Gender	Measurement Mean±SD	Range	p-value
Male	64.53± 5.64	45.73-70.64	0.464
Female	60.45± 5.79	44.46-73.74	

Table 6: Acetabular morphometric measurement-Posterior acetabular sector angle (PASA)

Gender	Measurement Mean±SD	Range	p-value
Male	91.64± 7.64	73.63-108.57	0.275
Female	91.64± 6.75	76.39-106.74	

Discussion

Acetabular depth is important in restoring normal hip mechanics and establishing a good range of movement. It is considered a contributing factor in component dislocation. As a result, to get a better insight, the present study was compared with that of other workers. Mukhopadhaya B et al carried out a study on 100 hip joints of 50 adults obtained from medicolegal post-mortem cases. [8] Three measurements i.e. the depth of acetabulum and the radii of acetabulum and the femoral head were made on each hip. They found that the mean depth of acetabulum was 2.71 cm. Salamon A et al measured 30 macerated anatomical specimens of pelvic bones. [9] Mean acetabular depth was 30±3.2 mm (21-38 mm). Saikia KC et al recorded the mean depth of acetabulum was 2.5 cm. [10]

In the present study, the mean depth of acetabulum is 26.17±2.83 (20.26-32.32). The mean depth of the present study coincides with the study done by Mukhopadhaya B et al. [11] Lang C et al studied a series of mostly unorthodox measurements on a sample of 45 (19 females and 26 males) dry hip bones from the Grant Collection, curated in the Medical Sciences Building at the University of Toronto. [12] They found that the mean acetabular depth in males and females was 29.00 mm (SD-3.80) and 26.64 mm (SD- 2.93) respectively. Mean values for the male group were higher in all cases. These higher values indicate that males have larger measurements dealing with the inner structures of the pelvis. [13] .Kim YH measured the equatorial and meridian diameter of acetabulum in 655 Korean adult cadavers and 172 Korean fetuses with a caliper by taking the greatest width of the cavity (a1), and the depth was measured using two wires. The mean depth of acetabulum in male and female was 20.3 mm and 18.1 mm respectively. [14]

Arsuaga JL et al studied 34 linear variables and 10 non-metrical (morphological) characters in a series of 418 adult hip bones of known sex (227 males and 191 females) born in the Beira Litoral region of Portugal between 1820 and 1920. The mean acetabular depth in males and females was 25.1 mm (SD = 2.6) and 22.8 mm (SD = 2.2) respectively. They found that acetabulum were deeper in men than in women in both hips and this was significant (P< 0.01 right hip, P < 0.02 left hip). [15] Chauhan R et al carried out the dissections of fifty-four cadaveric hip joints belonging to the age group of 50-70 years of both sexes. Average depth of acetabulum (in mm) on the right side and left side of male was 27.49±2.70 (23.0-34.0) and 28.18±2.58 (24.3-34.0) respectively. Similarly, average depth of acetabulum (in mm) on the right side and left side of female was 24.68±1.20 (23.0-26.0) and 25.70±2.11 (23.0-28.0) respectively. It was observed that the depth of the acetabulum was greater in males than females both on right and left side. On the right side the difference being statistically significant (right p= 0.02, left P = 0.06). According to Murtha PE et al the mean depth of acetabulum in male and female was 22.7 mm and 19.5 mm respectively. [16]

Msamati BC et al found the mean acetabular depth in 52 males on right side was 31.7 mm (12.0- 32.0; SD- 1.55) and on left side was 31.8mm (15.0- 33.0; SD- 1.86). Mean acetabular depth in 38 females on right side was 29.5 (23.0-38.0; SD- 2.06) and on left side was 29.8 (24.0-39.0; SD- 2.12). Acetabulum were deeper in men than in women in both hips and this was significant (P< 0.01 right hip, P < 0.02 left hip). [17] Saikia KC et al found the mean values of acetabular depth was identical between males:2.5 cm (1.6-5.6 cm) and females: 2.5 cm (1.4-5.2

cm). [10] Papaloucas C et al carried out the measurements of 200 hip bones within the Greek population. It was found that in males, in comparison to the females acetabular depth was larger. [18] The mean depth of male and female acetabulum of the present study almost coincides with the mean depth found by the Arsuaga JL et al. [19]

In the present study, the mean DA in male > female. Similar finding was observed in all other studies except the study of Saikia KC et al where they found identical values of mean acetabular depth between males and females. [10] In the present study a statistically significant difference ($P < 0.01$) was found when the mean depth of acetabulum was compared between male and female. Mukhopadhaya B et al found that the mean depth of acetabulum on right and left side was 2.465 cm (2.13-3.03) and 2.451 cm (2.13-3.65) respectively. [8] Saikia KC et al found the mean values of acetabular depth was identical when comparison was made between right side: 2.5 cm (1.4-5.6 cm) and left side: 2.5 cm (1.4-5.6 cm). [10]

In the present study, the mean DA on Right > Left. The difference was statistically non-significant. The finding in the present study coincides with the study done by Mukhopadhaya B et al where the mean depth of acetabulum was greater on right side. [9] However, Saikia KC et al found identical values of mean acetabular depth between right and left sides. [10] Arsuaga JL et al found that there was no significant difference between the left and right hip within the same sex. [20] Chauhan R et al noticed that the depth of the left acetabulum was greater than that of the right side in both sexes but the difference was statistically insignificant (male $p = 0.34$, female $p = 0.20$). [21] Msamati BC et al also noted that the depth of left acetabulum was greater than that of the right side in both male and female but there was no significant difference between the left and right hip within the same sex. [22] Chibber et al suggest that left limb is dominant. Therefore, the dimensions of the bones forming the hip joint of left side should be more so as to bear greater loading force on femur. [23]

In the present study, in case of male the mean DA on Right > Left. In case of female the mean DA on Left > Right. The difference was statistically non-significant.

Conclusion

Scientific improvement urges researchers and practitioners in any field of medicine to deepen knowledge, resulting in emergence of specialties. Hip surgery being one of them requires more detailed knowledge, about the complex acetabular measurements. The depth studied on acetabulum in the present study showed statistically significant differences between males and females. Studies based on depth of acetabulum are relatively few in the literature, hence the findings of the present study can provide a guideline for further studies on acetabulum. Considering that total hip replacement is a common surgery performed now a day, awareness of the dimensions of the acetabulum is of immense importance to the orthopaedic surgeons. It will assist prosthetists to construct suitable prostheses. It will also help in detection of disputed sex by forensic experts.

References

1. Larson CM, Sikka RS, Sardelli MC, Byrd JW, Kelly BT, Jain RK et al. Increasing alpha angle is predictive of athletic-related “hip” and “groin” pain in collegiate National Football League prospects. *Arthroscopy*. 2018;29(3):405-10
2. Yugesh K, Senthil Kumar. Morphometric analysis of acetabulum and its clinical correlate in south Indian population. *International Journal of Applied Research*. 2017;2(6):1011-1014.
3. Dolan MM, Heyworth BE, Bedi A, Duke G, Kelly BT. CT reveals a high incidence of osseous abnormalities in hips with labral tears. *Clin Orthop Relat Res*. 2016;469(3):831-8.
4. Kraeutler MJ, Ashwell ZR, Garabekyan T, Goodrich JA, Welton KL, Flug JA et al. The iliofemoral line: a radiographic sign of acetabular dysplasia in the adult hip. *Am J Sports Med*. 2015;45(11):2493-2500.
5. Stewart MJ, Milford LW Fracture- Dislocation of the Hip: an end result study. *JBJS Am* 2015;36A 315-342.
6. Hesp WL, Goris RJ. Conservative treatment of fractures of the acetabulum. Results after longtime follow up. *Acta Chir Belg*. 2015; 88(1):27-32.
7. Ukoha U, Ukohaet, Judet J and Letourmel E. Fractures of the acetabulum: Classification and surgical approaches for open reduction. *JBJS Am* 1964;46A1615-1638)
8. Prasath A. Fractures of the acetabulum: Accuracy of reduction and clinical results in patients managed operatively within three weeks after the injury *JBJS Am*: 2014;78A 1632-1645) 66
9. Devi TB, Philip C. 2014. Acetabulum – Morphological and morphometrical study. *RJPBCS*, 2014;5(6):793 – 799.

10. Buiskstra Eric E,Johnson, Joel M Matta, Jeffrey W.Mast, Emile Letournel.Delayed reconstruction of acetabular fractures 21 -120 days following injury. Clin Orthop Relat Res 2013; 305: 20-30
11. Patel J, Bansal M,Arya D,Mehta CD. A study of anatomical parameters of hip joint in cadavers and its clinical importance. Cibtech journal of surgery, 2013;2(2):44-50.
12. Varma CL,raju PK,rajeshwari T. Parameters of hip joint on human cadavers. Rrjmhs, 2013;2(3):33-39.
13. Smitha M, Shailaja CM, Angadi AV, Patil RS. Morphometrical study of acetabulum in central Karnataka region. Anatomica Karnataka, 2013;7(2):94-98.
14. Monazzam S, Agashe M, Hosalkar HS. Reliabilty of overcoverage parameters with varying morphologic pincer features: omparison of EOS and Radiography. Clin orthop Relat Res, 2013;471(8):2578-2585.
15. Laborie LB,Engstear IO,Lehmann,Sera F,Dezateux C,Engstaer LB,Rosendhal K.2013.Radiographic measurements of hip dysplasia at skeletal maturity – new reference intervals based on 2038 19 year old Norwegians. Skeletal radiology,27(6)1-14.
16. Parmara G, Rupareliab S, Patelc SV, Patelb SM, Jethvaa N. Morphology and morphometry of the acetabulum. Int j bio med res, 2013;4(1):2924-2926.
17. Vyas K, Bhavesh S,Zanzrukiya K. An osseous study of morphological aspect of acetabulum oh hip bone. Int j res med, 2013; 2(1):78-82.
18. Gaurang Parmara McKee MD, Garay ME, Schemitsch EH, et al. Irreducible fracturedislocation of the hip: a severe injury with a poor prognosis. J Orthop Trauma 2013; 12(4):223-229.
19. Dhindsa GS, Matta JM, Merritt PO. Displaced acetabular fractures. Clin Orthop Relat Res.2013; 230:83
20. Arsic S, Ilic D, Mitkovic M, Tufegdzc M,J ankovic S, Trajanovic M. Thestudy of morphological parameters of human acetabulum signficant for hip arthroplasty. APW, 2013.1:313.
21. Kebaish AS, Roy A, Rennie W: Displaced acetabular fractures: long-term follow-up, J Trauma 2012; 31:1539.
22. Gillard J, Pelt C, Linford S, Stoddard GJ, Peters C. Centre edge angle measurement for hip preservation surgery: technique and caveats. Clin Orthop. 2012;34(2):86.
23. Dudda M,kim YJ,Zhanj Y,Nevitt MC,Xu L,Niu J,Goggins J,Doherty M,Felson D. Morphological differences between chinese and caucasian female hips. Arthritis rheum 2011.;63(10):2992-2999.