

# Arthroscopic Treatment Of Knee Joint Synovial Chondromatosis

Lionel John<sup>1</sup>, Suresh Kumar J<sup>2\*</sup>, Vijay Narasimman reddy<sup>3</sup>

<sup>1,2,3</sup>Department of Orthopaedics, Sree Balaji Medical College and Hospital, Chrompet, Chennai-600044

\*Corresponding Author: Suresh Kumar J

<sup>2</sup>Department of Orthopaedics, Sree Balaji Medical College and Hospital, Chrompet, Chennai-600044.  
Email Id: jothilingamsuresh@gmail.com  
DOI:10.47750/pnr.2023.14.S01.120

## Abstract

A benign rare synovial proliferative disease, synovial chondromatosis is characterised through more than one cartilaginous nodules in synovial space. Most commonly affected joint is the knee joint. This is a case report of a male patient of age 18 years presented with right knee joint pain. On radiological assessment using MRI indicates moderate knee joint effusion with synovial thickening and multiple calcified and non-calcified loose bodies were identified. Synovectomy was performed to remove several loose bodies and synovial membrane which was sent to histopathological examination. The results suggest that the procedure, arthroscopy, is an effective diagnostic and therapeutic tool for synovial chondromatosis.

**Keywords:** Synovial Chondromatosis, knee joint, arthroscopy.

## INTRODUCTION:

Synovial chondromatosis which is also referred to as synovial osteo-chondromatosis, is a uncommon benign disorder characterised through multiple cartilaginous nodules believed to be loose tissues in the synovial joints<sup>[1]</sup>. This affects the single large joints, where knee joint being the most common, and the hip, elbow, shoulder, and ankle also reported later<sup>[2]</sup>. However, it also affects the smaller joints, especially the distal radio-ulnar, tibio-fibular, metacarpo-phalangeal and metatarso-phalangeal joints<sup>[3-5]</sup>. Clinical features may vary from being completely asymptomatic to symptomatic with subtle history of pain, associated with swelling, joint crepitus or may also present with history of locking of the knee joint<sup>[6]</sup>. Diagnosis is mainly based on radiological investigation like X-Rays and computed tomography scans. The tools used for definitive diagnosis are Magnetic resonance imaging (MRI) and Histopathological examination. This disorder is clinically managed by excision of loose bodies using arthroscopic technique to avoid further joint destruction<sup>[7]</sup>. This is a case of synovial chondromatosis of the knee in adult patient with pain in knee joint for past 5 years.

## CASE REPORT:

A male patient of age 18 years came to outpatient department with past history of trauma to right knee 5-years ago and currently presented with complaints of increase in pain over right knee for the past 3 months. On clinical examination, there was a swelling associated with tenderness along medial joint line of right knee. The range of movements was found to be 0° to 70° and it was painful more than 70°. Special tests was not able to elicit due to pain. MRI of right knee showed multiple calcified and non-calcified loose bodies and moderate knee joint effusion with thickening.

Patient was posted for Arthroscopic Synovectomy with meniscal repair. Under Spinal Anaesthesia, patient in supine position, under tourniquet control standard Antero-medial, Antero-lateral, Supero-lateral and Supero-medial portals were used. ACL and PCL were intact. Multiple loose bodies seen. Loose bodies were reamed, washed and removed. Thorough wash was given. Loose bodies and synovial membrane were sent for histopathological examination.

Pathological gross specimen showed multiple grey white soft tissue bits altogether measuring about 3 x 2 cm and microscopy showed fragments of hyperplastic synovial tissue with a few dilated blood vessels, adjacent islands and nodules of cartilaginous tissue with dystrophic calcification, which was indicative of synovial chondromatosis.

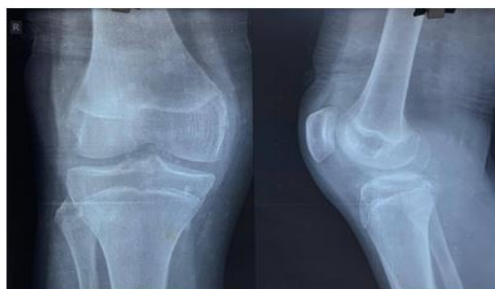
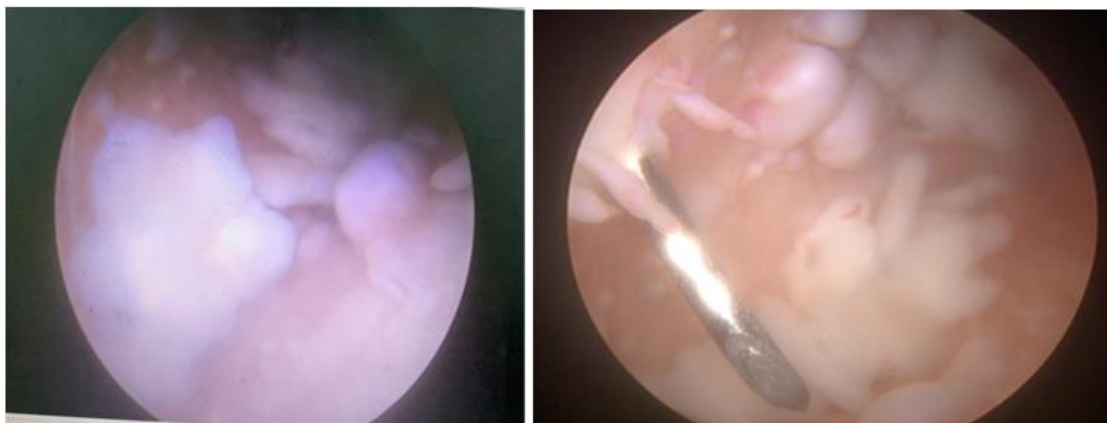


Figure 1: X Ray image of knee

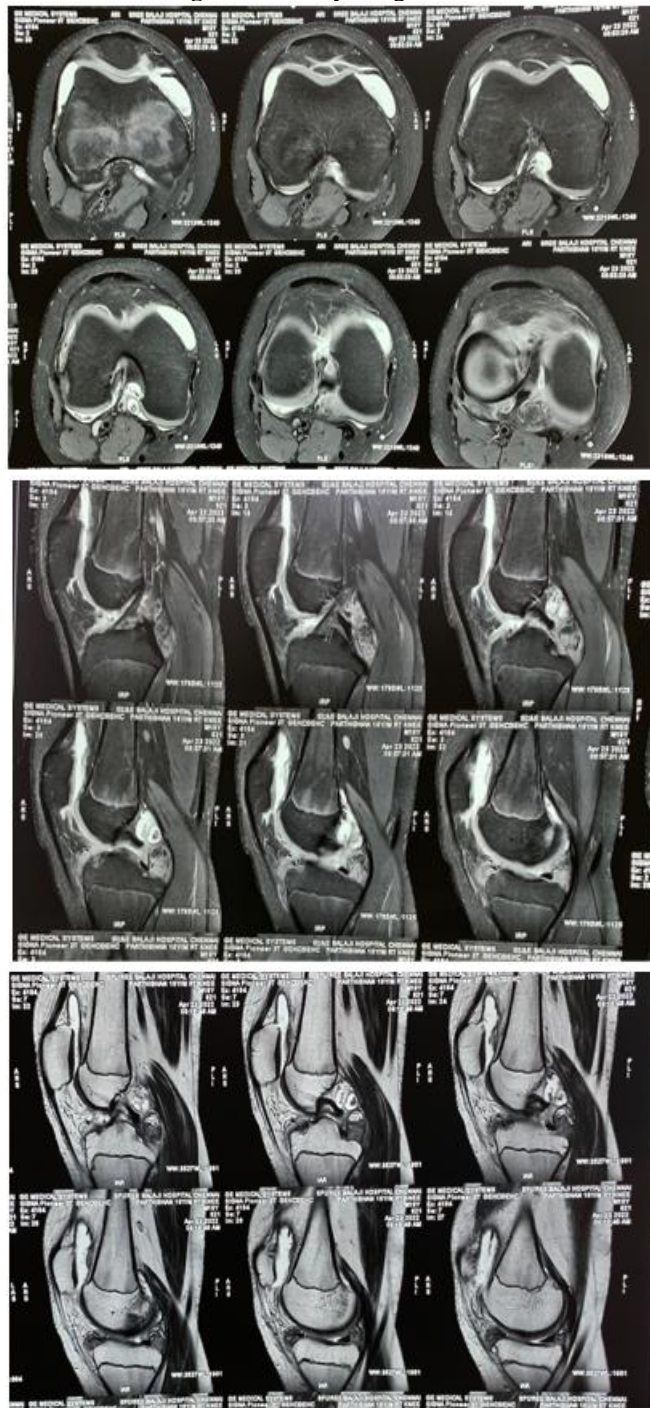

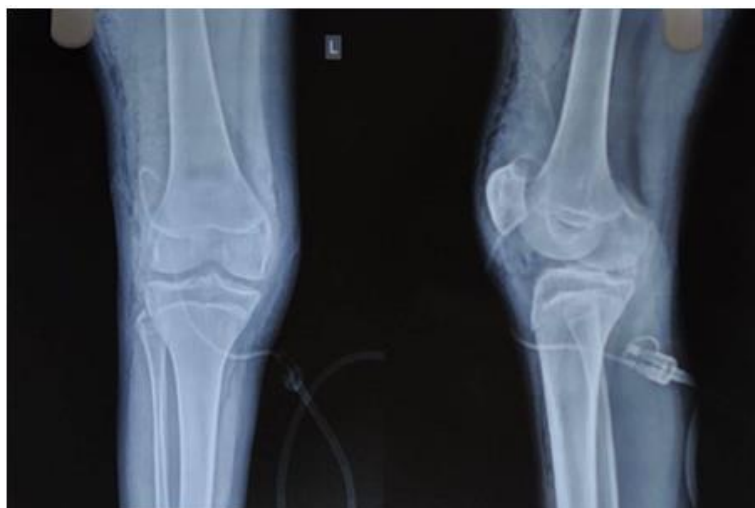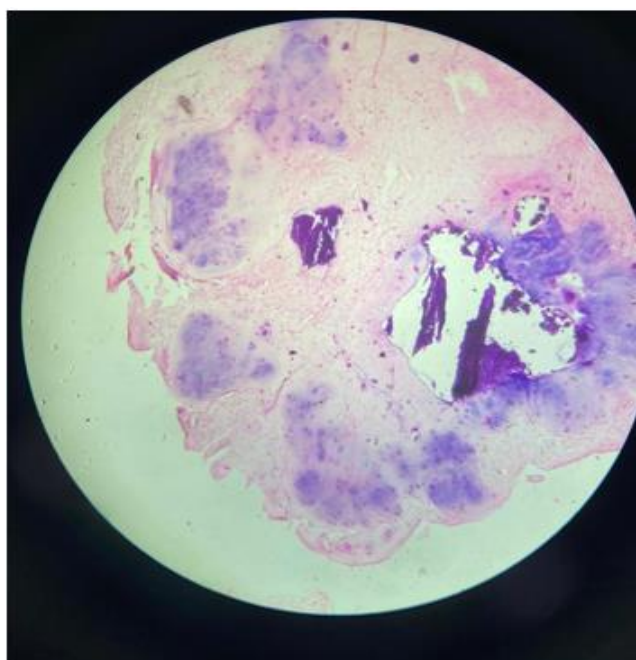
Figure 2: MRI scans showing loose bodies and moderate joint effusion



**Figure 3:** Arthroscopic image showing multiple loose bodies



**Figure 4:** Post-operative X Ray image



**Figure 5:** Histopathology image - Lobules of cartilage and dystrophic calcification

## DISCUSSION:

Synovial osteo-chondromatosis is an disorder with a underlying etiology associated with synovial metaplasia<sup>[8]</sup>. Cartilaginous nodules present in the synovium or in the joints leads to the formation of subchondral fibroblasts in the tendon and tendon sheath<sup>[9]</sup>. These extrusions from the synovial capsule turns out to be loose bodies that float in the synovial space or extend to extra articular soft tissues<sup>[10]</sup>

Milgram identified three stages of synovial chondromatosis based on gross and pathological observations. Stage I is referred to as active lesions of the synovium, without free bodies and metaplasia of synovial cartilage. Stage II is referred to as transitional lesions with active intra- synovial proliferation along with free loose bodies and these free bodies may remain within the proliferated membrane. Stage III is referred to as multiple loose bodies in joint space and synovitis subsides. During stages II and stage III, free body removal can be performed by partial or total synovectomy. This patient was diagnosed to be in stage III of the disorder.

Synovial chondromatosis is most common in individuals between the ages of 30 and 50<sup>[11]</sup>. For diagnosis, radiological examinations such as AP and lateral X-rays, as well as MRI scans, are required. X-ray and MRI revealed many irregular loose bodies with moderate joint effusion. In terms of post-surgical early recovery, shorter operating time, small incision, and complete instrumentation, arthroscopy has a better clinical outcome than arthrotomy, and arthroscopy has a more successful treatment outcome than loose body removal alone<sup>[12,13]</sup>.

According to Urbach et al, loose body removal by local synovectomy eliminates aberrant synovial tissue and prevents recurrence<sup>[14]</sup>.

In a study by Coolican et al, out of 18 knees, 14 knees were either symptom free or has only minor symptoms after arthroscopic removal of loose bodies. Out of these, three required two arthroscopic operations<sup>[15]</sup>.

## CONCLUSION:

This case report comes to a conclusion that the technique, arthroscopy, is safe and fruitful method in the treatment of synovial chondromatosis with loose bodies.

## CONSENT AND ETHICAL APPROVAL:

The authors have gathered and retained the patient's consent and ethical approval as per the university guidelines.

## COMPETING INTERESTS:

There are no competing interest stated by the authors.

## REFERENCE:

1. Milgram JW. Synovial osteochondromatosis: A histopathological study of thirty cases. *J Bone Joint Surg Am.* 1977;59:792-801. Pubmed
2. Roberts D, Miller TT, Erlanger SM. Sonographic appearance of primary synovial chondromatosis of the knee. *J Ultrasound Med.* 2004;23:707-709. Pubmed
3. Von Schroeder HP and Axelrod TS: Synovial osteochondromatosis of the distal radio-ulnar joint. *J Hand Surg Br.* 1996;21:30-32.
4. Batheja NO, Wang BY, Springfield D, Hermann G, Lee G, Burstein DE and Klein MJ. Fine-needle aspiration diagnosis of synovial chondromatosis of the tibiofibular joint. *Ann Diagn Pathol.* 2000;4:77-80.
5. Warne BA, Tigrani DY, Ward CM. Metacarpophalangeal joint synovial osteochondromatosis: A case report. *Iowa Orthop J.* 2008;28:91-93.
6. Evans S, Boffano M, Chaudhry S, Jeys L and Grimer R: Synovial chondrosarcoma arising in synovial chondromatosis. *Sarcoma.* 2014;647939.
7. Neumann JA, Garrigues GE, Brigman BE, Eward WC. Synovial Chondromatosis. *JBJS Rev.* 2016;4: pii: 01874474- 201605000-00005. Pubmed
8. Narasimhan R, Kennedy S, Tewari S, Dhingra D and Zardawi I: Synovial chondromatosis of the elbow in a child. *Indian J Orthop.* 2011;45:181-184.
9. Chen CY, Chen AC, Chang YH, Fu TS, Lee MS. Synovial chondromatosis of the hip: management with arthroscope-assisted synovectomy and removal of loose bodies: report of two cases. *Chang Gung Medical Journal.* 2003 Mar 1;26(3):208-14.
10. Birchall D, Khangure MS, Spagnolo DV. Vertebral synovial osteochondromatosis with compressive myelopathy. *Spine (Phila Pa 1976).* 1999;24:921-923. Pubmed
11. Jesalpura JP, Chung HW, Patnaik S, Choi HW, Kim JI and Nha KW: Arthroscopic treatment of localized synovial chondromatosis of the posterior knee joint. *Orthopedics.* 2010;33:49.
12. Samson L, Mazurkiewicz S, Treder M and Wiśniewski P. Outcome in the arthroscopic treatment of synovial chondromatosis of the knee. *Ortop Traumatol Rehabil.* 2005;7:391-396. Pubmed
13. Ogilvie-Harris DJ and Saleh K: Generalized synovial chondromatosis of the knee: A comparison of removal of the loose bodies alone with arthroscopic synovectomy. *Arthroscopy.* 1994;10:166- 170. Pubmed
14. Urbach D, McGuigan FX, John M, Neumann W, Ender SA. Long-term results after arthroscopic treatment of synovial chondromatosis of the shoulder. *Arthroscopy.* 2008;24:318-323.
15. Coolican MR, Dandy DJ. Arthroscopic management of synovial chondromatosis of the knee. Findings and results in 18 cases. *The Journal of bone and joint surgery.* British volume. 1989 May;71(3):498-500.