

One Year Clinical Evaluation Of Translucent Zirconia Crowns In Dental Esthetic Zone With Biologically Oriented Preparation Technique Versus Conventional Preparation (RCT)

Kareem Talaat^{1*}, Amina Zaki², Samaa Kotb³, Rasha Sami⁴

^{1*}Assistant lecturer of Fixed Prosthodontics department, Faculty of Dentistry, Cairo university, Giza, Egypt.

² Professor and Head of the Fixed Prosthodontics Department, Faculty of Dentistry, Cairo University, Giza, Egypt.

³Lecturer of Fixed Prosthodontics, Faculty of Dentistry, Cairo University, Giza, Egypt.

⁴ Assistant Professor of Fixed Prosthodontics, Faculty of Dentistry, Cairo University, Giza, Egypt.

*Corresponding Author: - Dr. Kareem Talaat, email: kareemtalaat@dentistry.cu.edu.eg

*Assistant lecturer, of Fixed Prosthodontics department, Faculty of Dentistry, Cairo university, Giza, Egypt.

DOI: 10.47750/pnr.2022.13.S08.511

Abstract

Statement of the problem: Tooth preparation with horizontal finish line requires removal of reasonable amount of tooth structure at the cervical area which affects the remaining tooth structure at this area. Therefore, more conservative preparation design such as biologically oriented preparation technique (BOPT) might be needed to save tooth structure at the cervical area.

The Purpose: To Evaluate the effect of Conventional preparation design (horizontal), and Biologically Oriented Preparation Technique (BOPT), on Marginal adaptation, fracture and gingival inflammation score of the translucent zirconia crown in dental esthetic zone.

Methodology: 44 monolithic translucent zirconia single crowns were fabricated in dental esthetic zone. The patients were separated randomly into two groups. Group1: (horizontal preparation design) Group2: BOPT. After final cementation. The Modified United States Public Health Service (MUSPH) criteria for restoration clinical evaluations were used to assess marginal adaptation. Gingival inflammation was assessed using gingival inflammation index. Evaluation of the restoration was at intervals of three, six, nine, and twelve months.

Results: Comparison between two groups at different intervals regarding marginal adaptation, fracture and gingival inflammation score revealed statistically insignificant difference.

Conclusions: Within limitations of the present one year follow up randomized clinical trial, the following conclusions could be drawn:

1. The conventional and BOPT preparation designs both clinically accepted to provide successful dental restoration
2. The lower gingival inflammation score of the restored teeth with the conventional preparation design compared to that of the BOPT, may not be conclusive as regard the study time frame, indicating that increasing the follow-up period might alter the present finding.

Clinical implications: Beyond of all the prosthodontic preparation techniques, knowledge of B.O.P.T. (Biological Oriented Preparation Technique) allows us to achieve predictable and consistent results in terms of periodontal health and gingiva architecture surrounding ceramic restoration. Nevertheless, long term studies are necessary to ensure the benefits of this techniques.

Key words: gingival inflammation score ,gingival margin, emergence profile, biologically oriented preparation technique, Vertical preparation . feather edge finish line.

INTRODUCTION:

Successful restorations depend on the idea of minimally invasive preparation; therefore, the goal of reconstructive dentistry is to achieve good aesthetic outcomes while also preserving biological features. To get around the fundamental limitations of veneering zirconia copings, full-contour monolithic zirconia crowns have recently taken the place of veneered zirconia. Excellent flexural strength and toughness, appropriate tooth color and translucency, little wear on opposing teeth, conservative tooth preparation, durability and improved esthetic making the monolithic zirconia a material of choice for dental restorations. With the development of extremely translucent zirconia blocks and blanks and advancements in CAD/CAM technology, it is now possible to create monolithic anterior and posterior crowns and fixed dental prostheses (FDPs) without the need for veneering or porcelain chipping. Cemented restoration's long-term success is significantly impacted by its marginal fit. Marginal fit is influenced by a variety of factors, one of which is

preparation designs. There are typically two basic types of preparation: vertical preparation, sometimes referred to as biologically oriented preparation (BOP), and horizontal preparation, which has finish lines. During horizontal preparations, the dentist places a precisely defined finish line that is caught during impression production and replicated in the model, while in BOPT, the laboratory technician selects the margins based on data obtained from gingival tissue. The BOPT can retain the healthiest tooth structure because it provides the thinnest marginal thickness. Although tapered and thin edges have certain drawbacks, such as difficulty processing precisely and sensitivity to chipping fracture so, using monolithic zirconia restoration can overcome this problem. Least invasive procedures are advised to avoid pulp damage or the weakening of remaining dental tissue. Therefore, it's crucial to use preparation designs that aren't overly invasive like BOPT. In the present clinical trial, the null hypothesis was that the clinical behavior would not be different among monolithic zirconia crowns with conventional (horizontal) or BOPT preparation designs.

MATERIALS AND METHODS:

Sample size:

A power analysis was designed to have adequate power to apply a 2-sided statistical test of the null hypothesis that there is no difference between biologically oriented preparation and conventional preparation in clinical behavior of single zirconia crown in dental esthetic zone. According to the results of (**Konstantinidis, Ioannis, et al 2018**)¹ the predicted sample size (n) was a total of (33) cases. Sample size was increased by (15%) to compensate for possible drop-outs during follow-up periods to be (44) cases i.e. (22) cases per group. Sample size calculation was performed using G Power version 3.1.9.4.

Research ethics approval

This study and the template informed consent form were reviewed by the Ethics Committee of Scientific Research - Faculty of oral and dental medicine – Cairo University and approved in September 2020. This study was performed in Fixed Prosthodontics Department clinics of Faculty of Dentistry, Cairo University, Egypt.

Case selection

Patients seeking to enhance esthetics were selected to receive a total of 44 translucent zirconia crowns. According to the number of crowns needed for each patient, a total of six patients were obtained. Each patient was provided by the information about the various treatment possibilities. Each patient's treatment strategy was outlined. They then consented to complete the informed consent form which was approved by the ethics committee of Cairo University's Faculty of Dentistry before beginning the clinical work.

Selection criteria

Inclusion criteria: All patients were required to have no active periodontal diseases, be physically and psychologically capable of withstanding standard dental treatments, be indicated for all ceramic crowns in maxillary esthetic zone as: badly decayed teeth, teeth restored with large filling restorations, endodontically treated teeth, malformed teeth, malposed teeth and spacing between maxillary teeth in esthetic zone

Exclusion criteria: Patient with active periodontal diseases failing to maintain good oral hygiene measure, pregnant women, patients with incompletely erupted teeth and patients with malocclusion or parafunctional habits

Allocation:

Independent researcher numbered the enrolled patients serially as 1, 2, 3, x according to the approval date. The independent researcher decided for the “odd” numbered patients to be allocated in the “Conventional preparation group” (Group I) , and the “even” numbered patients to be allocated in the “BOPT group”(Group II) .A total of six patients was enrolled in the present study.

Blinding:

In this clinical trial, two examiners - from the Fixed Prosthodontics Department Staffs, faculty of Dentistry, Cairo University - (who went through profound assessment training program including assessment chart with different techniques for measurement of outcomes) were responsible for the assessment of clinical outcomes. Any conflict in assessment between the 2 examiners, was solved by the main investigators.

Teeth preparation phase:

In all cases, tooth preparations were carried out by a single clinician. For conventional preparation 0.5 mm chamfer finish line was created using tapered stone with round end (1mm in diameter) (850-314-016, Komet, Germany) then the finish line was finished using yellow coded tapered stone with round in end (856EY-314-016, Komet, Germany.)

For BOPT Preparation was carried out using special stones called batt stone that has no abrasive at its tip gross reduction was done with cutting stone that has 140 μ (8851 314 012 KOMET, Germany) abrasive particles (Figure1) in this way, gingival tissue injury was reduced or eliminated and allow for tooth-guided preparation as reported by **Panadero et al 2020**² . Figure2 represent the finished BOPT in the day of reduction.



Figure 1: Batt cutting stone used in axial reduction for BOPT

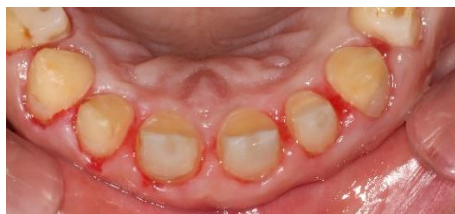

Figure 2: Shape of completed BOPT

Provisional restorations fabrication:

The index was filled with bis-acrylate resin composite material then placed on the patients' lubricated teeth after that the silicon index was taken off once the temporary material had fully set. Then proper finishing and polishing of the margins was done. Following that, non-eugenol based temporary cementation was performed. In BOPT group the impression was taken after 2 weeks of temporization to give the gingiva time for complete healing (figure 3)

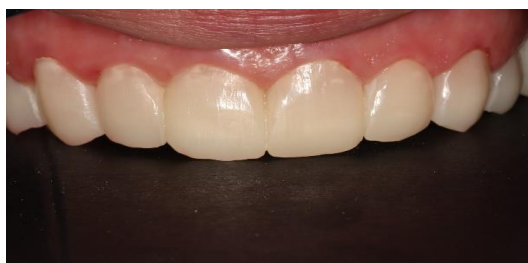

Figure 3 : Gingival condition 2 weeks after reduction

Tissue retraction:

A smooth cord packer was used to pack the retraction cord (ULTRPAK E ,ultradent ,USA)size 00 along the whole surface of the tooth, beginning from the mesial side and moving buccally, distally, and finally lingually. Packing was carried out carefully in direction toward the tooth to avoid tearing of the periodontal ligaments .Figures 4 represent the horizontal preparation after cord application. In BOPT group double retraction code technique was used to insure maximum lateral tissue displacement. we started by packing of size 00 retraction cord then application of size 0 retraction cord. Figures 5 represent the BOPT after cords application.

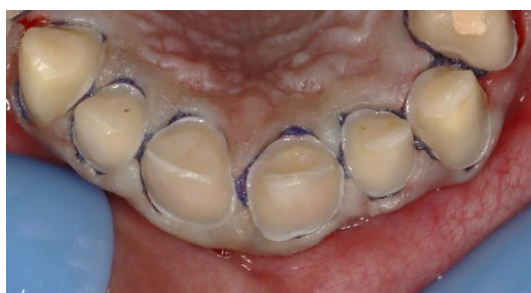

Figure 4: Horizontal Preparation After Retraction Cord Application

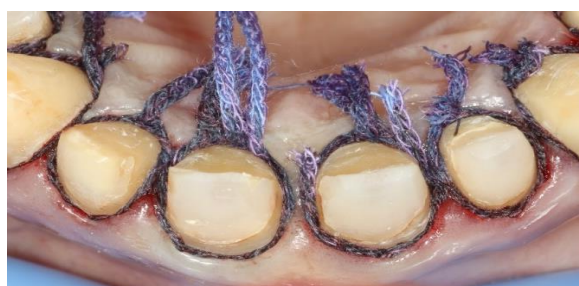

Figure 5: BOPT After Retraction Cords Application

Impression making phase:

Final impressions were made in plastic stock trays using Polyvinyl siloxane (PVS) addition silicon (Panasil, Kettenbach, Germany). The impression technique was double mix two steps: first, putty consistency was taken before the preparation, and then light body was taken after the preparation using an auto mixing tip and a dispensing gun, resulting in an accurately homogenous mix.

laboratory steps:

Die preparation for horizontal finish line group:

For horizontal finish line group, ditching was done apical to finish line using round bur to accentuate the finish line.

(B): Die preparation for BOPT group:

The proper retraction of the gingival tissue before impression allowed the clinician to identify the finishing area on the working model. With a 0.5 mm pencil, a black mark was traced over the gingival contour and projected onto the abutment's wall. Figure 6 signifies the gingival margin level after drawing the line.



Figure 6: After Marking of the gingival line on abutment walls

Then, using a circular bur, the gingival area surrounding the abutment was removed to reveal the subgingival portion of the preparation. The apical part of the preparation became exposed and was marked. The area between the gingival margin level and apical part of preparation called finishing area. Based on (Loi et al 2013)³ the restoration margin can be located at any part of the finishing area but preferable to be at the apical line (Figure 7)

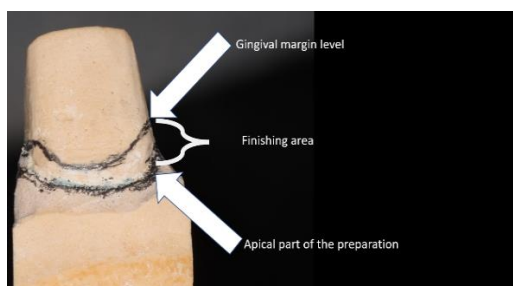


Figure 6: Finishing area

PMMA Restoration fabrication for try in :

The cast was scanned using Activity 885 (Renfert, Gernay). Designing of the restorations were done using exo-cad software. The designing parameters were set according to preparation design as following: For Horizontal finish line group gap distance 35 μ incisal and axial starting 1mm from margin while for BOPT group zero gap distance incisal and 30 μ axially were set started from margin⁴. Then PMMA restoration for try in were milled from PMMA discs (YAMAHACHI PMMA) using 4 axis milling machine (Roland DWX-50).

Verification for the resin restorations:

The resin restoration was checked first on the master cast for the seating, occlusion, and marginal fitting. The PMMA was tried to check marginal fit determined by moving sharp explorer from tooth to the restoration and from restoration to the tooth. Then shape, contacts, contour and finally the occlusion were examined. Then the PMMA restorations were used as a provisional restoration.

Final restoration fabrication:

The final restorations were fabricated from the Multi-layered translucent zirconia disc using 4 axis milling machine (Roland DWX-50) (dry milling). Sintering of final restorations was performed using a Mihm Vogt Tabeo sintering furnace. Then Vita Akzent plus staining kit (Vita Zahnfabrik) to stain all the restorations. This was done using the ceramic furnace Programat CS3 (Ivoclar Vivadent) at 850 °C firing Cycling. Then the final restorations were checked first on the master cast for the seating, occlusion, and marginal fitting.

Cementation of final restorations

Using a manual excavator, the PMMA restoration was then removed, and the abutment teeth were cleaned and gently dried by air. The finished restorations were then checked using all the verification steps processes, including seating , marginal integrity, retention, stability, and occlusion. Figure 89 represents the restorations just before final cementation. Radiographic checking of the final restorations was done to ensure marginal fitting by using periapical radiographs. Then the final restorations cemented using self-adhesive resin cement (Breez .Pentron ,USA)

Follow up and maintenance phase procedure:

Evaluation of the restoration at the time of cementation and at intervals of three, six, nine, and twelve months (**Figures 8-9**) This was accomplished by applying the MUSBH criteria for marginal adaptation :

- Alpha (A) No visible evidence of crevice along the margins; no catch or penetration of the explorer,
- Bravo (B) Visible evidence of crevice and/or catch of explorer, no penetration of the explorer.
- Charlie (C) Visible evidence of crevice and penetration of explorer

While gingival inflammation score for gingival inflammation evaluation:

0= Normal gingiva;

1= Mild inflammation: slight change in color and slight edema but no bleeding on probing

2= Moderate inflammation: redness, edema and bleeding on probing.

3= Severe inflammation: marked redness and edema, ulceration with tendency to spontaneous bleeding.

Figures 7 and 8 represents the groups after one year follow up.

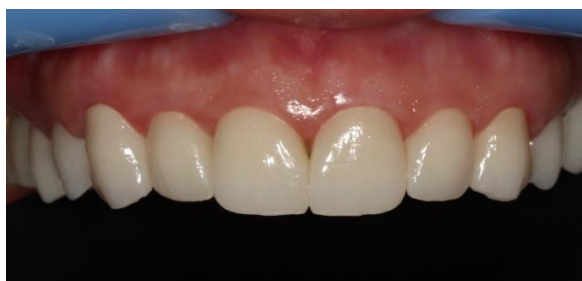

Figure 8 : crowns for horizontal preparation after 1 year follow up

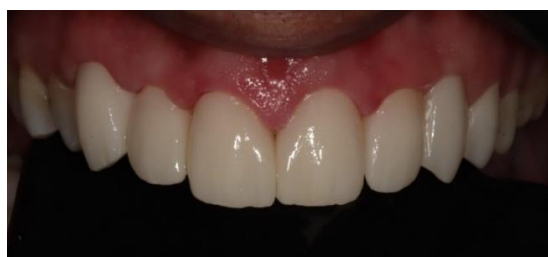

Figure 9 : crowns for BOPT after 1 year follow up

RESULTS:

1. Marginal adaptation: Statistical analysis results of the marginal adaptation for group I (conventional preparation) crowns and group II (BOPT) crowns are shown in table figure (10).

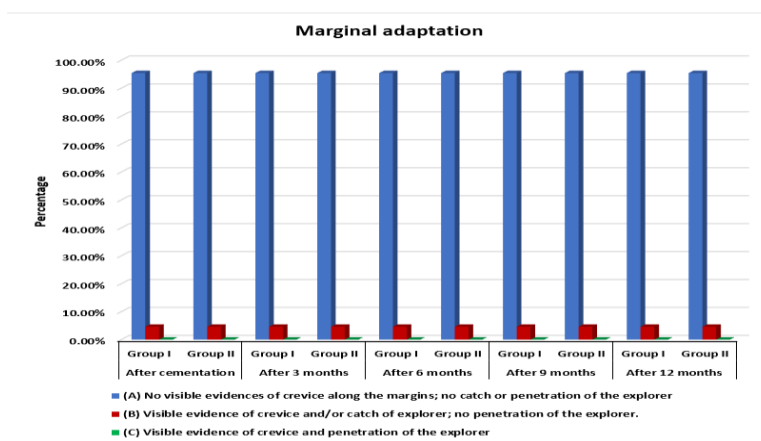


Figure (10): Bar chart showing percentages of (A), (B) and (C) categories of marginal adaptation in group I & group II at the different intervals and comparison between them.

From figure (9) regarding marginal adaptation:

- Comparison between both groups at different intervals revealed insignificant difference between them regarding marginal adaptation as $P > 0.5$. 42 crowns (21 crown in each group) (95.4%) shown no visible evidence of crevice along the margins; no catch or penetration of the explorer .Only two crowns (one crown in each group) (4.6%) shown Visible evidence of crevice and/or catch of explorer; no penetration of the explorer.

2. Gingival inflammation score: Statistical analysis results of the gingival inflammation score for group I (conventional preparation) crowns and group II (BOPT) crowns are shown in figure (11).

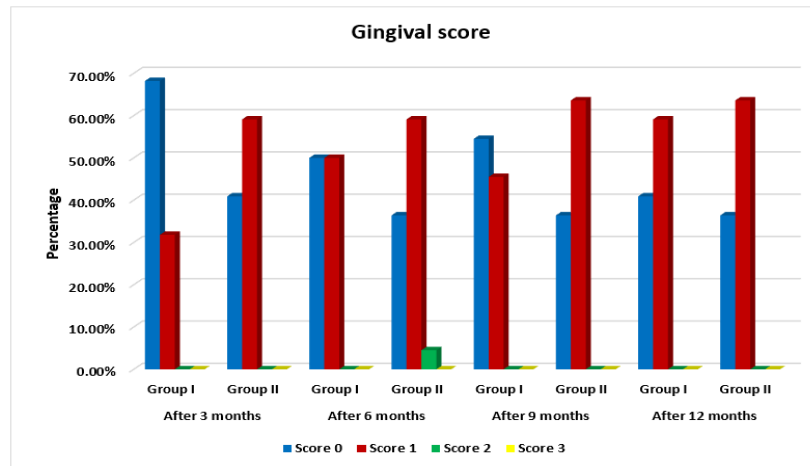


Figure (11): bar chart showing percentages of gingival evaluation score in both group I & group II at different intervals and comparison between them.

From figure (10) regarding gingival inflammation score :

-Comparison between both groups at different intervals revealed that gingival inflammation scores are slightly higher in group II rather than group I without statistically significant difference as $P > 0.05$

-Regarding group I:

- After 3 months 15 crowns (68.2%) shown score 0 while 7 crowns (31.8%) shown score 1.
- After 6 months 11 crowns (50%) shown score 0 while 7 crowns (50%) shown score 1.
- After 9 months 12 crowns (54.5%) shown score 0 while 10 crowns (45.5%) shown score 1.
- After 12 months 9 crowns (40.9%) shown score 0 while 13 crowns (59.1%) shown score 1.

-Regarding group II

- After 3 months 9 crowns (40.9%) shown score 0 while 13 crowns (59.1%) shown score 1.
- After 6 months 8 crowns (36.4%) shown score 0 while 13 crowns (59.1%) shown score 1 and only one crown shown score 2
- After 9 months 8 crowns (36.4%) shown score 0 while 14 crowns (63.6%) shown score 1.
- After 12 months 8 crowns (36.4%) shown score 0 while 14 crowns (63.6%) shown score 1

DISCUSSION

Over 12 months we investigated throughout this study the clinical behavior of monolithic translucent zirconia single crown in dental esthetic zone with two different preparation designs.

This investigation was a randomized triple-blinded clinical trial (trial participants, outcomes assessor and statistician were blinded), and to reduce the possibility of selection bias among the patients who were enrolled, simple randomization type was selected. Since the primary investigator carried out every procedure throughout this trial, the outcome had to be assessed by knowledgeable evaluators who were blinded and unaware of the patients' group identity. Tooth preparation for a full coverage restoration is relatively destructive and causes irreparable tooth structure loss. Several attempts have been made to determine the best method of tooth preparation for achieving an acceptable marginal fit and emergence profile and at the same time retaining more tooth structure throughout the preparation process.

Some studies reported that it has been possible for the clinician to use zirconia in very thin thickness up to 0.3 mm because of the development of its mechanical strength (K Haggag2018 and washa etal 2020)⁵. That allowed clinicians to conservatively prepare the tooth structure without affecting the structure durability of the final restoration (Ioli etal 2013)⁶. and Comlekoglu M etal(2018)⁷ described BOPT as a vertical preparation method that has the following characteristics ,ending the preparation the preparation sub-gingivally, and the end of this preparation may be located at different depths of the gingival sulcus, depending on the available biological width. As proven by several researches, the coronal seal is clearly better with BOPT than with horizontal finish line. This is due to the reduced space

between the teeth and crown margin caused by vertical geometry. It leads to a better fit, less cement exposure, and less bacterial penetration (Cagidiaco et al 2000)⁸. Additionally, BOPT is considered as a more conservative preparation than to horizontal preparation, particularly in the cervical part of the tooth⁶.

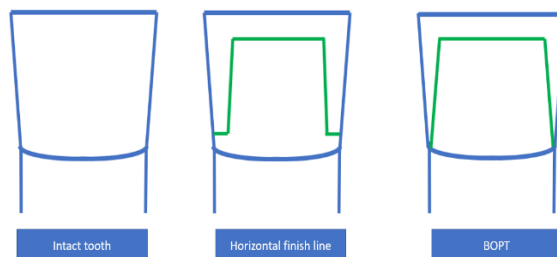


Figure (12): Schematic Diagram Showing The Difference In Amount Of Tooth Reduction Between Conventional Preparation And BOPT

BOPT is recommended for prosthetic restorations in which monolithic zirconium oxide crowns are planned. It can also be employed in the case of small teeth, where a more parallel preparation can result in improved retention, and in mandibular incisors, where constructing a shoulder finish line would result in practically full loss of the tooth's crown.^{9,10} Other researchers reported that rotary curettage causes bleeding but is restricted to the oral sulcular epithelium and newly healed epithelium is thicker and adheres more tightly to a new prosthetic restoration; however, it is conditioned by the fabrication of a highly exact, smooth, and polished temporary and final restoration¹¹. On the contrary, dental clinicians who oppose BOPT claiming that it causes permanent injury to periodontal attachments during the rotary curettage and may violate biological width during preparation¹¹.

(Panadero et al 2020)¹² recommended the use of special stone with a non-working tip (batt stone) that reduces or eliminate harm to the tissue and allow for tooth-guided preparation. Accordingly, all the BOPT preparations of group II were carried out using this batt stone.

Regarding the control group a chamfer finish line design 0.5mm was selected as it requires less invasive preparation than that with shoulder or rounded shoulder finish line. Furthermore, from the clinical point of view, chamfer finish lines exhibited marginal adaptation better than shoulder finish line. Also. This finish line is suggested for all ceramic restorations over the shoulder. Because of its rounded internal angles and thickness, it improves the biomechanical performance of single zirconia restorations¹³.

Translucent zirconia crowns in this study were fabricated using CAD/CAM technology and the cement gap was set during desining of the final restoration for conventional preparation to be at least 30 μ as space less than 30 μ would lead to in -complet seationg of the restoration ,this was folling the guidelines of . Zero gap distance space at incisal edge of BOPT group was set to prevent restoration form over seating during final cementation as there is no horizontal stoper (finish line) that stop the seating of the restoration as recommended by Magallanes Ramos et al (2017)¹¹.

Based on the results of our work, the null hypothesis was accepted as there was no statistically significant difference between the two groups in all investigated outcomes.

One of the most important criteria for the clinical quality and success of all ceramic crowns is marginal fit. A crown with a greater marginal discrepancy favors high rate of cement dissolution. Microleakage from the oral cavity can result in secondary caries and vital pulp inflammation. Furthermore, poor crown marginal adaptation increases plaque retention and alters the composition of the subgingival microflora, indicating the onset of periodontal.

On one hand, for marginal adaptation results for BOPT, the alpha score in could be attributed to the fact that the margins can be placed within the sulcus. This margin of the final restoration can be located at different levels within the finishing area, without harming the quality of fit and without invading the epithelial attachment.

This finding was in agreement with Lorenzo Breschi et al (2020)¹⁴ how studied the clinical outcome regarding marginal adaptation and fracture of single zirconia crowns with chamfer versus feather edge finish line and they found that no statistically significant differences between the two group.

Our results were similar to (Carlo, E et al 2012)¹⁵ how investigated the clinical performance of monolithic zirconia crown using The modified California Dental Association (CDA) criteria in retrospective study, they found that crowns with knife-edge margins provided clinical performance similar to that reported with other margin designs.

On the other hand, results were contradicting (Comlekoglu et al. 2009)¹⁶, who investigated the influence of four different finish line designs (chamfer, mini-chamfer, feather edge, and rounded shoulder) on the marginal fit of zirconia crowns and found that knife edge preparation had better marginal adaptation than other designs. They stated that because the restoration margin finishes with an acute angle (knife edge), the distance between the restoration margin

and the tooth is reduced.

Because gingival health around restoration is an evidence of successful restoration, gingival inflammation was included as an objective in this study. Clinical investigations reveal that even when plaque is properly managed, restorative margins may create unwanted tissue damage because of other iatrogenic procedures such as violation of biological width or traumatic gingival retraction. Within the period of follow up, a detailed examination of the findings indicates that the BOPT had a higher gingival inflammation score than the conventional preparation. This might be because those subgingival restorations are likely to facilitate retention of bacterial plaque and difficult to be cleaned by patient. This finding agreed with the findings of (Ponize et al 2017)¹⁷, who investigated if a deep chamfer preparation had a different effect in the periodontium than a feather edge preparation in the maxillary anterior zone. They concluded that vertical tooth preparations may pose a risk to periodontal tissues and should be used with caution during tooth preparation, provisional restoration fabrication, impression procedures, and cementation as there is a statistically significant difference in bleeding on probing between the baseline and the 12-month follow-up. On probing, the feather edge preparation shows substantially more bleeding than the chamfer.

Our finding were also coinciding with Ferrari Cagidiaco and Endoardo (2019)¹⁸ findings, after studying the relationship between the position of the restoration margin and inflammation incidence. They found a higher probability of bleeding on probing expected in cases with feather-edge preparation and discovered a strong link between gingival inflammation and the distance of the crown margin below the gingival crest. Reaching to the end, The BOPT combined with monolithic zirconia and great advancements in CAD/CAM technology have opened the field for providing a conservative prosthetic approach with huge predictability in its marginal adaptation. Care must be given to the location of the margin within the sulcus to decrease the incidence of gingival inflammation.

CONCLUSION:

Within limitations of the present one year follow up randomized clinical trial, the following conclusions could be drawn:

1. The conventional and BOPT preparation designs - not showing any difference regarding marginal adaptation, marginal discoloration, fracture, and patient satisfaction- made them both clinically accepted to provide successful dental restoration.
2. The lower gingival inflammation score of the restored teeth with the conventional preparation design compared to that of the BOPT, may not be conclusive as regard the study time frame, indicating that increasing the follow-up period might alter the present finding.

RECOMMENDATION:

1. Whenever the clinical situation permits, the conventional preparation design for tooth preparation is recommended.
2. BOPT is recommended in cases when horizontal finish line is difficult to achieve such as cases with limited ferrule, teeth with constricted cervical area and need meticulous gingival retraction, impression that accurately record the gingival sulcus and qualified lab technician that has knowledge about BOPT
3. Further long-term studies are required to evaluate clinical performance and patients' satisfaction for translucent zirconia crowns with BOPT.

REFERENCES:

1. **Kontonasaki, E., Rigos, A. E., Ilia, C. and Istantos, T:** Monolithic Zirconia: An Update to Current Knowledge. Optical Properties, Wear, and Clinical Performance. Dent. J., 2019
2. **Pawel Labno and Krzysztof Drobniak** Comparison of horizontal and vertical methods of tooth preparation for a prosthetic crown, Journal of Pre-Clinical and Clinical Research, {2020}, volume=14 (25-28)
3. **Loi I, Di Felice A.** Biologically oriented preparation technique (BOPT): a new approach for prosthetic restoration of periodontically healthy teeth. Eur J Esthet Dent. 2013 volume (1) pages :10-23.
4. **Lorenzo Breschi, A. Comba, F. Del Bianco** CHAMFER VS FEATHER EDGE FOR A SINGLE ZIRCONIA CROWNS journal of dentistry October 2020
5. **K Haggag, M Abbas, H Ramadan.** Effect of thermo-mechanical aging on the marginal fit of two types of monolithic zirconia crowns with two finish line designs. ADJ-for Grils. 2018; 5: 121-8
6. **Loi I, Di Felice A.** Biologically oriented preparation technique (BOPT): a new approach for prosthetic restoration of periodontically healthy teeth. Eur J Esthet Dent. 2013 volume (1) pages :10-23
7. **Comlekoglu M, Dundar M, Özcan M, Gungor M, Gokce, B, Artunc C.** Influence of cervical finish line type on the marginal adaptation of zirconia ceramic crowns. Operative dentistry. 2019; 34:586-92
8. **Cagidiaco MC, Ferrari M, Berteili.** Cement thickness and microleakage under metal-ceramic restorations with a facial butted margin: an in vivo investigation. Int J Periodont Rest Dent 2000 ;4:324-331
9. **Euán R, Figueras-Álvarez O, Cabratosa-Termes J, Brufau-de Barberà M, Gomes-Azevedo S.** Comparison of the Marginal Adaptation of Zirconium Dioxide Crowns in Preparations with Two Different Finish Lines. J Prosthodont. 2012.
10. **Mitov G, Anastassova-Yoshida Y, Nothdurft FP, Von See C, Pospiech P.** Influence of the preparation design and artificial aging on the fracture resistance of monolithic zirconia crowns. J Adv Prosthodont. 2016. doi: 10.4047/jap.2016.8.1.30
11. **Magallanes Ramos R, Clark D, Mazza M, Venuti P, Maiolino M, Kopanja S, Cirimpei V, Tawfik AA, Bordonali D, Acatrinei B, Sutradhar JC, Czerwinski M, A Sienkiewicz JK.** The Shoulderless Approach A New Rationale in Prosthetic Dentistry. Tomorrow Tooth Journal. i. Published 2017. Accessed November 20, 2019
12. **Panadero R, Pastor B , Loi I, Suárez M , Pelaez J.** Clinical behavior of posterior fixed partial dentures with a biologically oriented preparation technique: A 5-year randomized controlled clinical trial. J Prosthet Dent. 2020; 20: 1-7.
13. **Labno P & Drobniak K:** Comparison of horizontal and vertical methods of teeth preparation for a prosthetic crown. J Pre-Clin Clin Res., 2020 volume 14: 25–28.

14. **Lorenzo Breschi, A. Comba, F. Del Bianco** CHAMFER VS FEATHER EDGE FOR A SINGLE ZIRCONIA CROWNS journal of dentistry October 2020
15. **Carlo E. Poggio, Riccardo Dosoli, Carlo Ercoli**, A retrospective analysis of 102 zirconia single crowns with knife-edge margins, The Journal of Prosthetic Dentistry, 2012, Volume 107, Issue 5,
16. **Comlekoglu M, Dundar M, Özcan M, Gungor M, Gokce, B, Artunc C.** Influence of cervical finish line type on the marginal adaptation of zirconia ceramic crowns. Operative dentistry. 2019; 34:586-92
17. **Paniz G, Nart J, Gobbato L, Chierico A, Lops D, Michalakis K.** Periodontal response to two different subgingival restorative margin designs: a 12-month randomized clinical trial. Clin Oral Investig. 2016
18. **Ferrari Cagidiaco, Edoardo**, "Randomized Clinical Trial on Single Zirconia Crowns with Feather-Edge vs Chamfer Finish Lines: Four-Year Results." International Journal of Periodontics & Restorative Dentistry, 2019.