

Protective and Ameliorative Effect of The *Tinospora cordifolia* Extract Against Cisplatin Effect on Sperm Parameters of Males Rats

Mohannad Abdulrazzaq Gati Al Nasiri¹

¹Department of Biology, College of Science University of Thi-Qar.

Abstract

Infertility is the biggest problem be facing doctors for treating the patients that undergo the different types of cancer disease. Since the chemotherapies drugs have an adverse effect on the testis tissue and, therefore, sperm quality. Cisplatin is used one of the most potent and widely used for treating ovarian cancer, lung carcinoma, and lymphoma. Cisplatin causes testicular degeneration and decreases sperm quality. Natural antioxidants drove from plants and fruits reduce the negative impact and have productive properties against anticancer drugs. *Tinospora cordifolia* is a medicinal herb from India used as a potential natural complementary treatment for specific health conditions, which is used as an immunity improved, anti-inflammatory, antioxidant and anticancer. Thus, this study aimed to evaluate the protective and ameliorative effect of the *Tinospora cordifolia* against adverse cisplatin on reproductive parameters. In this study, 40 healthy adult male rats were used in four groups control, cisplatin-induction, and two deferent concentration of aqueous extract of *Tinospora cordifolia*. The result showed an improvement effect of aqueous extract of *Tinospora cordifolia* administered by gavage at 200 mg/kg concentration against Cisplatin.

Keywords: Reproductive parameters, Infertility, Cisplatin, *Tinospora cordifolia*, sperm parameters and testicular degeneration.

INTRODUCTION

The chemotherapy medication is a well-established treatment modality, while the previous studies proved chemotherapy represents a potentially serious unexpected risk for patient harm (Rinke et al., 2007; Weingart et al., 2018). A common chemotherapy harm included testicular toxicities sequentially leading to infertility in males (Alabedi et al., 2021; Cooper et al., 2010) and polycystic ovary in females (Alibraheemi et al., 2021). Generally, cisplatin is one of the most potent and widely used drugs for treating cancers such as ovarian, lung, lymphomas, and others (T.-E. Wang et al., 2020). Previous studies found that using cisplatin as an anticancer is accompanied by severe side effects concurrently occurring in healthy tissues as testes (T.-E. Wang et al., 2020). Since cisplatin binds to the nuclear DNA and mitochondria DNA (mtDNA), which leads to inhibition of cell cycle and leads to cytotoxicity (Keshtmand et al., 2014), in both normal and cancer cells (Al-Mousaw et al., 2022; T.-E. Wang et al., 2020).

The focal functions of testes are to produce sperm and steroid hormones therefore, the adverse and degradative effect of the cisplatin on the testis tissue leads to testicular degeneration (Mohammadnejad et al., 2012). Moreover, studies reported that cisplatin causes impairment of male reproductive functions and decreased sperm parameters (Akamolafe et al., 2022). Earlier studies confirmed that cisplatin induces reactive oxygen species in different cells (Han et al., 2019; T.-E. Wang et al., 2020; Wangpaichitr et al., 2017). The global attention becomes on the natural antioxidant derived from the plants and fruits to face the adverse effect of the anticancer drugs (Al-Mousaw et al., 2022; Bustani et al., 2022).

Address for correspondence: Mohannad Abdulrazzaq Gati Al Nasiri,
Department of Biology, College of Science University of Thi-Qar

This is an open access journal, and articles are distributed under the terms of the Creative Commons Attribution-NonCommercial-ShareAlike 4.0 License, which allows others to remix, tweak, and build upon the work non-commercially, as long as appropriate credit is given and the new creations are licensed under the identical terms.

For reprints contact: pnrjournal@gmail.com

How to cite this article: Mohannad Abdulrazzaq Gati Al Nasiri, Protective and Ameliorative Effect of The *Tinospora cordifolia* Extract Against Cisplatin Effect on Sperm Parameters of Males Rats, J PHARM NEGATIVE RESULTS 2022;13:215-220.

Access this article online

Quick Response Code:



Website:
www.pnrjournal.com

DOI:
10.47750/pnr.2022.13.03.034

The *Tinospora cordifolia* is a medicinal herb from India. It has the potential to be a natural complementary treatment for specific health conditions as improved immunity (Alexander et al., 2010), antioxidant (Kumar et al., 2018), and anti-inflammatory (Hussain et al., 2015). Strides suggested that *Tinospora cordifolia* has blood purification properties (Mittal et al., 2014; Sharma et al., 2010). Researchers proved that *Tinospora cordifolia* improved the reproductive parameters and improved the hormonal equilibrium (Dhama et al., 2016).

Thus, our study aimed to evaluate the protective and ameliorative effect of the *Tinospora cordifolia* against adverse cisplatin on reproductive parameters, including sperm characteristics testicular histological findings.

Material and Methods

Animals: - In this investigation, 40 healthy adult male rats were used; the animal was purchased from the animal house of the University of Kufa, Faculty of science, and housed in an animal house of Iraqi central of the researcher. The animal weighed 200–225 g.

Extraction of aqueous extract of (*Tinospora cordifolia*)

Tinospora cordifolia was identified by an agricultural college at the University of Baghdad in Iraq. *Tinospora cordifolia* root was harvested, cleaned, dried, powdered, and extracted. The extract was created by 36 hours of refluxing with double-distilled water. The cooled liquid extract was powdered by evaporating its liquid contents. The section yielded about 22%, just before oral administration in rats, the section was re-dissolved in distilled water.

Cisplatin

Cisplatin was purchased from pharmaceutical centers in Bagdad, Iraq, and the other chemicals were obtained from Sigma centers.

Experimental design

The animals were divided randomly into four groups equally, and each group contained 10 rats. The first group was indicated as the control group since distilled water was injected intraperitoneally, while the second group was determined as a negative control since cisplatin was

intraperitoneally injected at 7mg/kg dosage at signal dose (Ateşşahin et al., 2006; Çeribaşı et al., 2010), on other hand third and fourth group was treatment group which besides the intraperitoneal injection of cisplatin at 7mg/kg dosage than that treated with aqueous extract of *Tinospora cordifolia* suspended in corn oil administered by gavage at 100 and 200 mg/kg respectively for 15 days (Alexander et al., 2010). All animals of each group were sacrificed after 45 days of experimental period and the samples were collected.

Sperm parameters

At the end of experimental periods, the Epididymal sperm concentration, motility (general and individual), viability, morphology, acrosomal integrity and abnormal sperm rate was evaluated. Moreover, the histological section was obtained for testicular degeneration.

Statistical analysis

PRISM Graphpad 8 was used to analyze and present the data; the obtained data was checked for normal distribution using the Shapiro–Wilk test. A mixed-model analysis of variance (2-way ANOVA) was used to compare mean differences between treatment groups; significance was tested using a mixed model (repeated measures 2-way ANOVA) value less than ($P > 0.05$) was considered statistically significant. Present data were presented as mean \pm and standard error mean (SEM).

Results

Sperm parameter in the table 1 and 2 showed ameliorative effect of two doses of *Tinospora cordifolia* on the sperm parameters. Since observed value (mean \pm SE) of seminal parameters included motility, viability and concentration illustrated in table-1, the outcome of negative control showed value decreased significantly lower than all groups in motility (general and progressive), viability, and concentration. In other hand, the result proved the improved effect of the *Tinospora cordifolia* against the cisplatin. Since the treatment groups are significantly higher than negative control in all sperm parameters; additionally, there are significant differences between the control and the treatment group in terms of motility, while there are no significant differences between treatment 2 group and control in terms of viability and concentration.

Table-1: Evaluation the Protective and Ameliorative Effect of The *Tinospora Cordifolia* Against Cisplatin on Sperm Parameters

Group	Motility		Viability	Concentration
	General	Progressive		
Control	89.5 \pm 0.2 a	82 \pm 0.5 a	90 \pm 1.5 a	13.5 \times 50 \times 10 ⁶ a
Negative Control	30.2 \pm 2.5 b	25 \pm 4 b	20 \pm 2 b	4.1 \times 50 \times 10 ⁶ b
Treatment 1	78.5 \pm 0.2 c	71 \pm 0.2 c	77 \pm 0.5 c	11.9 \times 50 \times 10 ⁶ a
Treatment 2	80.0 \pm 0.2 c	77 \pm 0.4 ac	84 \pm 0.25 ac	13.5 \times 50 \times 10 ⁶ a

Values are means \pm SEM of 40 adults female Wistar rats.

abcd Means values between groups with different superscripts are significantly different at ($P < 0.05$).

Control group; Received placebo only.

Induction group; Intraperitoneal injection of cisplatin at (7mg/kg).

Treatment 1:- aqueous extract of *Tinospora cordifolia* administered by gavage at 100 mg/kg.

Treatment 2: aqueous extract of *Tinospora cordifolia* administered by gavage at 200 mg/kg.

Table 2 showed the negative effect of cisplatin on acrosomal integrity and sperm morphology. Moreover, the result significantly proved the ameliorative effect of the *Tinospora Cordifolia* on acrosomal integrity and morphology. On the other hand, the negative group showed that cisplatin has a significant negative impact on both term acrosomal and morphology integrity compared with all groups. While the treatment groups in table 2 exhibited the improvement impact of *Tinospora Cordifolia* significantly compared with the negative group.

Table-2: Evaluation of the Protective and Ameliorative Effect of The *Tinospora Cordifolia* Against Cisplatin on Sperm Parameters

	Acrosomal integrity	Morphology
Control	98.2 ± 0.13 a	94.72 ± 0.82 a
Negative Control	92.7 ± 0.50 b	89.7 ± 2.0 b
Treatment 1	96.3 ± 0.10 c	92.50 ± 0.10 b
Treatment 2	97.85 ± 0.12 a	95.67 ± 0.27 b

Values are means ± SEM of 40 adults female Wistar rats.

abcd Means values between groups with different superscripts are significantly different at (P < 0.05).

Control group; Received placebo only.

Induction group; Intraperitoneal injection of cisplatin at (7mg/kg).

Treatment 1:- aqueous extract of *Tinospora cordifolia* administered by gavage at 100 mg/kg.

Treatment 2: aqueous extract of *Tinospora cordifolia* administered by gavage at 200 mg/kg.

During the study, histopathology revealed that the section testicular differentiation occurred. Histopathological examination of the control group reveals that the seminiferous tubules are normal in size with all stages of spermatogenesis and that the lumen is filled with the sperm-containing extract. Since the Cisplatin group showed regressed size seminiferous tubules, most seminiferous tubules show marked degeneration, with no spermatogenic series in the tubular lumen. While the treatment group seminiferous tubular size was almost restored to normal, sperm was also observed in the lumen, as shown in the figure 1.

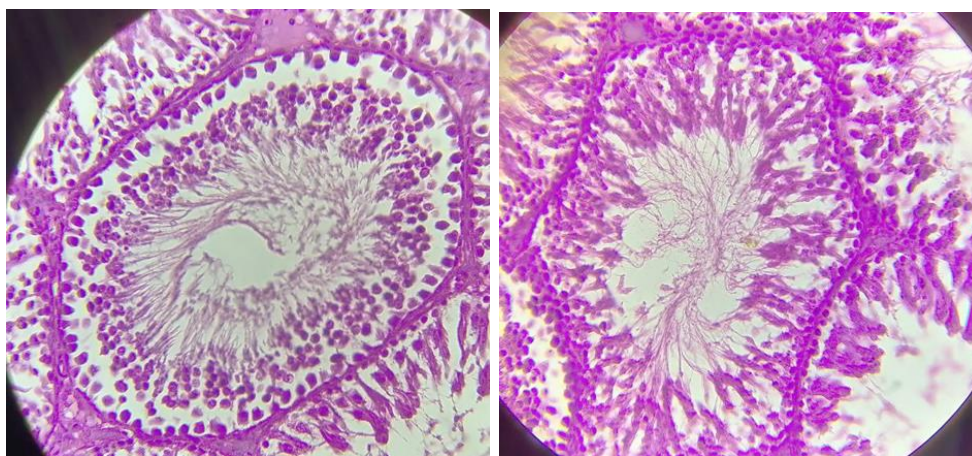


Figure 1: Control rat testis with normal histological structure of active mature functioning seminiferous tubules associated with the spermatogenic stage series. The peripheral layer of cells is made up of spermatocytes, spermatids, and finally spermatozoa to be released into the lumen.

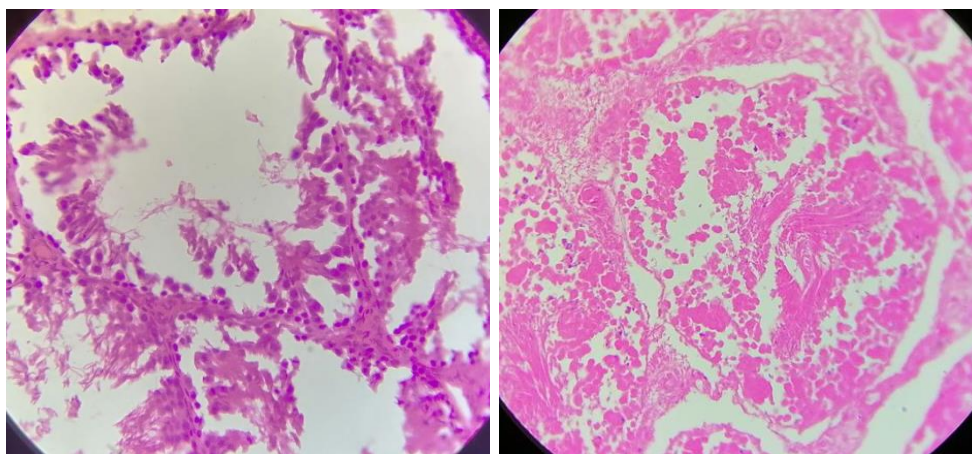


Figure 2: induction group (negative groups) Degenerated stem cell, with numerous normally-oriented, vacuolated cytoplasm of section, few sperms, intact basement membrane, separation of basal and abluminal cellular compartments in some.

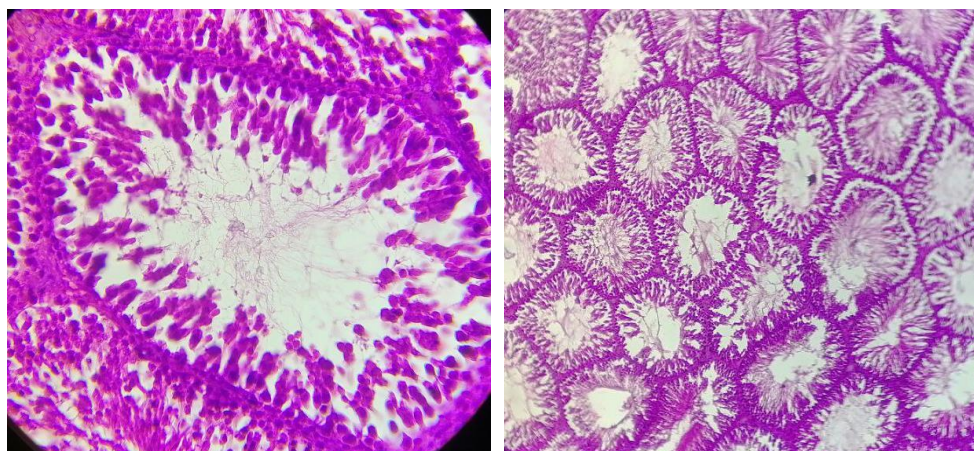


Figure 3: treatment group showing normal histological appearance and seminiferous tubular size was almost restored to normal, sperm was also observed in the lumen

Discussion

The functional mechanism of cisplatin that induced degeneration on testis is still not well known, but many recent studies indicate an essential role for the reactive oxygen metabolites in the pathogenesis of this effect (Ateşşahin et al., 2006; Kleih et al., 2019); it has been proposed that lipid peroxidation raised from cisplatin is the primary mechanism responsible for induced testicular damage (Aldemir et al., 2014; Bustani et al., 2021). Furthermore, previous studies showed that glucose- 6-phosphate dehydrogenase and hexokinase activity induced by the cisplatin. These reasons stimulate the damaged mitochondria to produce reactive oxygen species, increasing free radical production while decreasing antioxidant production (Catanzaro et al., 2015). As a result, shown in the sperm parameters value in Tables 1 and 2 and the histological section on figures two comparatives with

control in figure 1, moreover, our result proved that adverse effect of cisplatin on the testis tissue and spermatogenic stage as approved with previous studies (Almeer et al., 2018; L. Wang et al., 2020; Yucel et al., 2019). The reduction in sperm motility and morphology in the cisplatin group may be due to lipid peroxidation in membranes fatty acids, resulting in a loss of function (Baiee et al., 2018). Antioxidant has a productive impact against any oxidant stress arising from the toxic material (Paital et al., 2016) or anticancer drug (Al-Mousaw et al., 2022). Previous studies showed natural antioxidants from the plant as lycopene (Arain et al., 2018), curcumin (Alibraheemi et al., 2021), and *Ocimum tenuiflorum* (Alabedi et al., 2021) had a protective effect against the adverse effect of the different anticancer drugs as Filgrastim and Cyclophosphamide (Al-Mousaw et al., 2022; Alabedi et al., 2021). Moreover, the current result illustrated the productive effect of the *Tinospora cordifolia* as antioxidant and anti-inflammatory effect which improved the sperm parameters and testicular tissue section in histological

test as showed in the figure 3 comparative with figure 2. The previous studies proved that *Tinospora cordifolia* has anticancer (Ali et al., 2013), anti-inflammatory (Hussain et al., 2015) and antioxidant (Prince et al., 1999), properties and activity as showed in the result was improved all sperm parameters in table 1 and 2 spatially in used aqueous extract of *Tinospora cordifolia* administered by gavage at 200 mg/kg. Thus can used the aqueous extract as protective and improvement substance with anticancer drugs.

Conclusion

Finally, the histopathological section shows that cisplatin is related to pathological effects on testis and sperm quality and can decrease by using an aqueous extract of *Tinospora cordifolia* administered by gavage at 200 mg/kg, which improve the sperm parameters and protective the testicular tissue against the adverse effect of cisplatin.

REFERENCES

1. Akomolafe, S. F., Oyeleye, S. I., & Oboh, G. (2022). Effect of cashew (*Anacardium occidentale* L.) nut-supplemented diet on steroidogenic enzymes, hormonal and oxidative imbalances, and sperm parameters in cisplatin-induced reproductive toxicity in male rats. *Journal of Food Biochemistry*, e14100.
2. Al-Mousaw, M., Bustani, G. S., Barqaawee, M. J. A., & AL-Shamma, Y. M. (2022). Evaluation of histology and sperm parameters of testes treated by lycopene against cyclophosphamide that induced testicular toxicity in Male rats. *AIP Conference Proceedings*, 2386(1), 20040.
3. Alabedi, T., AL-Baghdady, H. F., Alahmer, M. A., Bustani, G. S., & Al-Dhalimy, A. M. (2021). Effect of *Ocimum tenuiflorum* on Induced Testicular Degeneration by Filgrastim in Wistar Rats. *Archives of Razi Institute*.
4. Aldemir, M., Okulu, E., Kösemehmetoğlu, K., Ener, K., Topal, F., Evirgen, O., Gürleyik, E., & Avcı, A. (2014). Evaluation of the protective effect of quercetin against cisplatin-induced renal and testis tissue damage and sperm parameters in rats. *Andrologia*, 46(10), 1089–1097.
5. Alexander, C. P., Kirubakaran, C. J. W., & Michael, R. D. (2010). Water soluble fraction of *Tinospora cordifolia* leaves enhanced the non-specific immune mechanisms and disease resistance in *Oreochromis mossambicus*. *Fish & Shellfish Immunology*, 29(5), 765–772.
6. Ali, H., & Dixit, S. (2013). Extraction optimization of *Tinospora cordifolia* and assessment of the anticancer activity of its alkaloid palmatine. *The Scientific World Journal*, 2013.
7. ALIBRAHEEMI, N. A. A., BUSTANI, G. S., & AL-DHALIMY, A. M. B. (2021). Effect of Curcumin on LH and FSH Hormones of Polycystic Syndrome Induced by Letrozole in Female Rats.
8. Almeer, R. S., & Abdel Moneim, A. E. (2018). Evaluation of the protective effect of olive leaf extract on cisplatin-induced testicular damage in rats. *Oxidative Medicine and Cellular Longevity*, 2018.
9. Arain, M. A., Mei, Z., Hassan, F. U., Saeed, M., Alagawany, M., Shar, A. H., & Rajput, I. R. (2018). Lycopene: a natural antioxidant for prevention of heat-induced oxidative stress in poultry. *World's Poultry Science Journal*, 74(1), 89–100.
10. Ateşşahin, A., Şahna, E., Türk, G., Çeribaşı, A. O., Yılmaz, S., Yüce, A., & Bulmuş, Ö. (2006). Chemoprotective effect of melatonin against cisplatin-induced testicular toxicity in rats. *Journal of Pineal Research*, 41(1), 21–27.
11. Baiee, F. H., Wahid, H., Rosnina, Y., Ariff, O., Yimer, N., Jeber, Z., Salman, H., Tarig, A., & Harighi, F. (2018). Impact of *Eurycoma longifolia* extract on DNA integrity, lipid peroxidation, and functional parameters in chilled and cryopreserved bull sperm. *Cryobiology*, 80, 43–50.
12. Bustani, G. S., & Baiee, F. H. (2021). Semen extenders: An evaluative overview of preservative mechanisms of semen and semen extenders. *Veterinary World*, 14(5), 1220.
13. Bustani, G. S., Jabbar, M. K., AL-Baghdady, H. F., & Al-Dhalimy, A. M. B. (2022). Protective effects of curcumin on testicular and sperm parameters abnormalities induced by nicotine in male rats. *AIP Conference Proceedings*, 2386(1), 20042.
14. Catanzaro, D., Gaude, E., Orso, G., Giordano, C., Guzzo, G., Rasola, A., Ragazzi, E., Caparotta, L., Frezza, C., & Montopoli, M. (2015). Inhibition of glucose-6-phosphate dehydrogenase sensitizes cisplatin-resistant cells to death. *Oncotarget*, 6(30), 30102.
15. Çeribaşı, A. O., Türk, G., Sönmez, M., Sakin, F., & Ateşşahin, A. (2010). Toxic effect of cyclophosphamide on sperm morphology, testicular histology and blood oxidant-antioxidant balance, and protective roles of lycopene and ellagic acid. *Basic & Clinical Pharmacology & Toxicology*, 107(3), 730–736.
16. Cooper, T. G., Noonan, E., Von Eckardstein, S., Auger, J., Baker, H. W., Behre, H. M., Haugen, T. B., Kruger, T., Wang, C., & Mbizvo, M. T. (2010). World Health Organization reference values for human semen characteristics. *Human Reproduction Update*, 16(3), 231–245.
17. Dhama, K., Sachan, S., Khandia, R., Munjal, A., MN Iqbal, H., K Latheef, S., Karthik, K., A Samad, H., Tiwari, R., & Dadar, M. (2016). Medicinal and beneficial health applications of *Tinospora cordifolia* (Guduchi): a miraculous herb countering various diseases/disorders and its Immunomodulatory effects. *Recent Patents on Endocrine, Metabolic & Immune Drug Discovery*, 10(2), 96–111.
18. Han, Y., Kim, B., Cho, U., Park, I. S., Kim, S. I., Dhanasekaran, D. N., Tsang, B. K., & Song, Y. S. (2019). Mitochondrial fission causes cisplatin resistance under hypoxic conditions via ROS in ovarian cancer cells. *Oncogene*, 38(45), 7089–7105.
19. Hussain, L., Akash, M. S. H., Ain, N.-U., Rehman, K., & Ibrahim, M. (2015). The analgesic, anti-inflammatory and anti-pyretic activities of *Tinospora cordifolia*. *Advances in Clinical and Experimental Medicine*, 24(6), 957–964.
20. Keshntmand, Z., Oryan, S., Ghanbari, A., & Khazaei, M. (2014). Protective effect of *Tribulus terrestris* hydroalcoholic extract against cisplatin-induced cytotoxicity on sperm parameters in male mice. *Int J Morphol*, 32(2), 551–557.
21. Kleih, M., Böpple, K., Dong, M., Gaißler, A., Heine, S., Olayioye, M. A., Aulitzky, W. E., & Essmann, F. (2019). Direct impact of cisplatin on mitochondria induces ROS production that dictates cell fate of ovarian cancer cells. *Cell Death & Disease*, 10(11), 1–12.
22. Kumar, V., Singh, S., Singh, A., Dixit, A. K., Srivastava, B., Sidhu, G. K., Singh, R., Meena, A. K., Singh, R. P., & Subhose, V. (2018). Phytochemical, antioxidant, antimicrobial, and protein binding qualities of hydro-ethanolic extract of *Tinospora cordifolia*. *Journal of Biologically Active Products from Nature*, 8(3), 192–200.
23. Mittal, J., Sharma, M. M., & Batra, A. (2014). *Tinospora cordifolia*: a multipurpose medicinal plant-A. *Journal of Medicinal Plants*, 2(2).
24. Mohammadnejad, D., & Abedelahi, A. (2012). Degenerative effect of cisplatin on testicular germinal epithelium. *Advanced Pharmaceutical Bulletin*, 2(2), 173.
25. Paital, B., Panda, S. K., Hati, A. K., Mohanty, B., Mohapatra, M. K., Kanungo, S., & Chainy, G. B. N. (2016). Longevity of animals under reactive oxygen species stress and disease susceptibility due to global warming. *World Journal of Biological Chemistry*, 7(1), 110.
26. Prince, P. S. M., & Menon, V. P. (1999). Antioxidant activity of *Tinospora cordifolia* roots in experimental diabetes. *Journal of Ethnopharmacology*, 65(3), 277–281.
27. Rinke, M. L., Shore, A. D., Morlock, L., Hicks, R. W., & Miller, M. R. (2007). Characteristics of pediatric chemotherapy medication errors in a national error reporting database. *Cancer*, 110(1), 186–195.
28. Sharma, V., & Pandey, D. (2010). Beneficial effects of *Tinospora cordifolia* on blood profiles in male mice exposed to lead. *Toxicology International*, 17(1), 8.
29. Wang, L., He, Y., Li, Y., Pei, C., Olatunji, O. J., Tang, J., Famurewa, A. C., Wang, H., & Yan, B. (2020). Protective Effects of Nucleosides-Rich Extract from *Cordyceps cicadae* against Cisplatin Induced Testicular Damage. *Chemistry & Biodiversity*, 17(11), e2000671.
30. Wang, T.-E., Lai, Y.-H., Yang, K.-C., Lin, S.-J., Chen, C.-L., & Tsai,

- P.-S. (2020). Counteracting cisplatin-induced testicular damages by natural polyphenol constituent honokiol. *Antioxidants*, 9(8), 723.
31. Wangpaichitr, M., Wu, C., Li, Y. Y., Nguyen, D. J. M., Kandemir, H., Shah, S., Chen, S., Feun, L. G., Prince, J. S., & Kuo, M. T. (2017). Exploiting ROS and metabolic differences to kill cisplatin resistant lung cancer. *Oncotarget*, 8(30), 49275.
 32. Weingart, S. N., Zhang, L., Sweeney, M., & Hassett, M. (2018). Chemotherapy medication errors. *The Lancet Oncology*, 19(4), e191–e199.
 33. Yucel, C., Arslan, F. D., Ekmekci, S., Ulker, V., Kisa, E., Yucel, E. E., Ucar, M., Ilbey, Y. O., Celik, O., & Basok, B. I. (2019). Protective effect of all-trans retinoic acid in cisplatin-induced testicular damage in rats. *The World Journal of Men's Health*, 37(2), 249–256.