

Management Of Black Triangles - A Review

Dr.Kajal¹, Dr.Priyanka Aggarwal^{2*}, Dr.Shweta Bali³, Dr.Amit Garg⁴, Dr.ArunaNautiyal⁵, Dr.Vaishali Rai Sharma⁶

¹PG 1st year, Department of Periodontics and Oral Implantology, Santosh Dental College/ Santosh University

²Professor, Department of Periodontics and Oral Implantology, Santosh Dental College/ Santosh University

³Professor & HOD, Department of Periodontics and Oral Implantology, Santosh Dental College/ Santosh University

⁴Professor, Department of Periodontics and Oral Implantology, Santosh Dental College/ Santosh University

⁵Sr. Lecturer, Department of Periodontics and Oral Implantology, Santosh Dental College/ Santosh University

⁶PG 1st year, Department of Periodontics and Oral Implantology, Santosh Dental College/ Santosh University

Corresponding author: Dr. Priyanka Aggarwal

DOI: 10.47750/pnr.2022.13.S04.225

Abstract

Introduction:In the present sphere, aesthetics and beauty is a major worry for many people, in the field of dentistry. Beauty of gingiva is one of the main factors to be considered in success of restorative dental care. Black triangle is the result of interdental papilla deficiency. The major complaints by the patients of black triangle are aesthetic problems, phonetic problems, food impaction, oral hygiene maintenance problems. One of the major difficult task is to overcome and correct interdental papillary deficiency. Etiological factors related to interdental papillary deficiency are periodontal disease, loss of the interdental bone related to the concerned papilla, length of embrasure area, angulation of root, location of contact points interproximally.

Objective:This review article attempts to present an overview on the various treatment modalities in management of black triangle.

Discussion and Conclusion: An interdisciplinary approach by the periodontist, orthodontist, prosthodontist and restorative dentist may be required for the management and correction of this soft tissue defect. It is essential if a predictable clinical results is to be achieved. Before starting the treatment patient should be made aware about the etiology and all the treatment alternatives. An esthetic regeneration of the interdental papilla can be gained by maintaining the height of interdental papilla.

Keywords: Black triangle, Interdental papilla, Aesthetics, Interdisciplinary approach.

RESUMO...

Introdução: Na presente esfera, a estética e a beleza são uma grande preocupação para muitas pessoas, no campo da medicina dentária. A beleza da gengiva é um dos principais fatores a considerar no sucesso dos cuidados dentários restaurativos. Triângulo preto é o resultado da deficiência da papila interdental. As principais queixas dos doentes do triângulo negro são: problemas estéticos, problemas fonéticos, afetação alimentar, problemas de higiene oral. Uma das principais tarefas difíceis é ultrapassar e corrigir a deficiência papilar interdental. Os fatores etiológicos relacionados com a deficiência papilar interdental são a doença periodontal, a perda do osso interdental relacionado com a papila em causa, o comprimento da área de embrasure, angulação da raiz, a localização dos pontos de contacto interproximamente.

Objetivo: Este artigo de revisão tenta apresentar um visão geral sobre as várias modalidades de tratamento na gestão do triângulo negro.

Discussão e Conclusão: Pode ser necessária uma abordagem interdisciplinar pelo periodontista, ortodontista, prosthodontista e restaurador dentista para a gestão e correção deste defeito dos tecidos moles. É essencial para que se alcancem resultados clínicos previsíveis. Antes de iniciar o tratamento, o paciente deve ser sensibilizado sobre a

etiologia e todas as alternativas de tratamento. Uma regeneração estética da papila interdental pode ser obtida mantendo a altura da papila interdental.

Palavras-chave: Triângulo preto, papila interdental, estética, abordagem interdisciplinar.

INTRODUCTION -

Interdental papilla is a part of gingiva which occupies embrasure area. Loss of interdental papilla (Figure 1) leads to a condition known as “Black triangle”. Black triangles are rated as the third most disliked esthetic problem after caries and apparent crown margins.¹

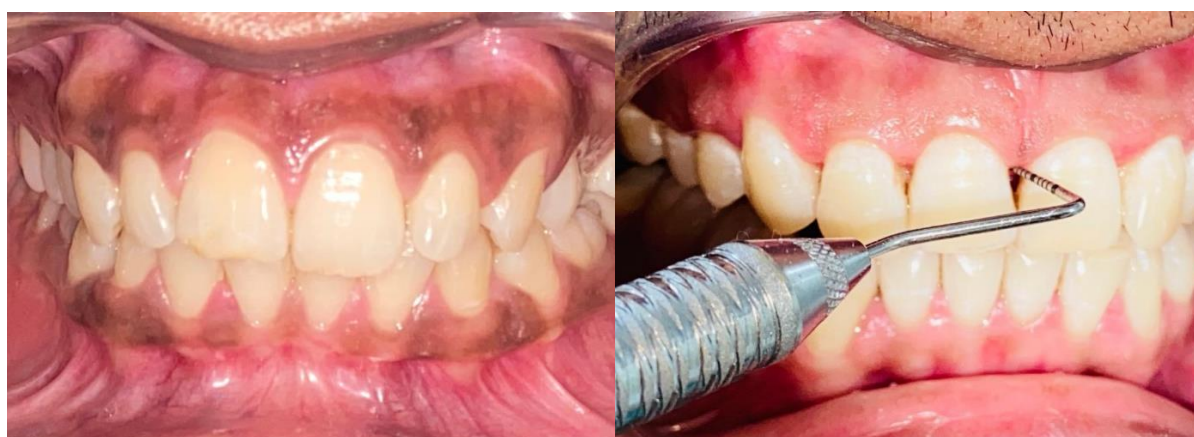

Figure 1. A. Normal interdental papilla. B. Black triangle between maxillary central incisors.

Anatomy of Interdental papilla: The interdental gingiva is a close-knit connective tissue, having a layer of oral epithelium on it and hold the interdental embrasure area.² The contact points of the teeth, the width of the adjacent tooth surfaces, and the trajectory of the cemento-enamel junction determines the morphology of interdental papilla. The morphology of the interdental papilla was described by Cohen³. In the anterior region, interdental papilla is narrow with a pyramidal shape and in the posterior region, it is broader with concave col having a bridge shape.

The absence of interdental papilla leads to chronic retention of food which subsequently affects periodontal health. And, it also causes aesthetic problem as well as phonetic problems by allowing the passage of air and saliva.⁴ Reconstruction of papillary deficiency is one of the most difficult and challenging treatments.

The objective of present review is to discuss the management of black triangle around natural teeth in detail.

ETIOLOGY OF BLACK TRIANGLE

There are many causative factors causing black triangle (Figure 2).

1. recession, loss of alveolar bone - caused by plaque
2. Traumatic oral hygiene procedures
3. Abnormal tooth shape
4. Restoration with irregular contours
5. Spacing between teeth
6. Tooth loss

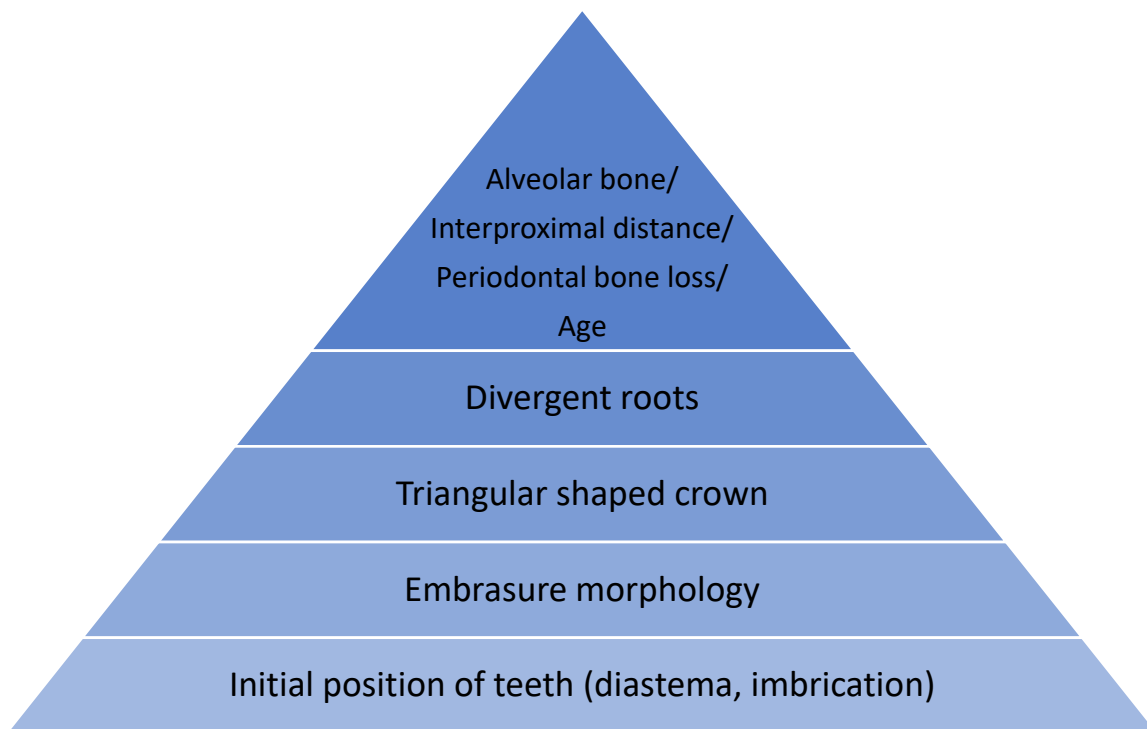


Figure 2. Hierarchy of etiological factors of black triangle.

Black triangles may also manifest post periodontic and orthodontic treatment. Its management varies depending on the etiological factor but it is favourable to manage it by teamwork usually including restorative, orthodontic and periodontic treatment.⁵

CLASSIFICATION OF BLACK TRIANGLE

Nordland and Tarnowin 1998 had proposed a classification using Contact point, facial apical extent of CEJ and interproximal CEJ as reference poin.⁶ They classified black triangles into four categories(Figure 3):

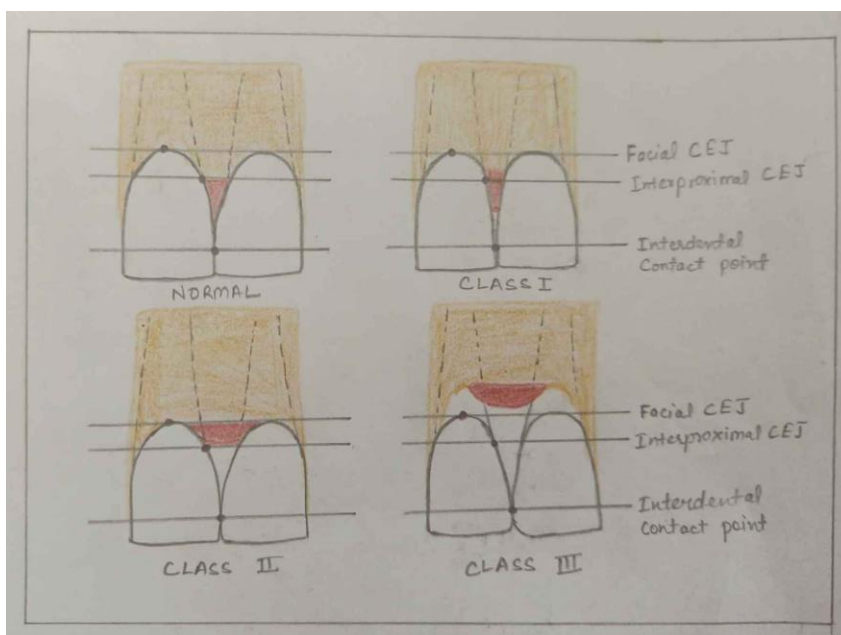


Figure 3. Classification of Black Triangle (Nordland and Tarnow 1998)

Normal: Interdental papilla fills embrasure space to the apical extent of the interdental contact point/area.

Class I: The tip of interdental papilla lies between the interdental contact point and the most coronal extent of CEJ.

Class II: The tip of the interdental papilla lies at/or the apical to the interproximal CEJ but coronal to the apical extent of the facial CEJ.

Class III: The tip of the interdental papilla lies at level with or apical to the facial CEJ.

Cardaropoli gave a classification based on the positional relationship in between the papilla, CEJ, and adjacent teeth to assess interproximal papillary level.⁷

PPI 1 (Papilla Presence Index score-1): When the papilla is completely present and coronally extends to the contact point and is at the same level as the adjacent papillae.

PPI2(Papilla Presence Index score-2): Papilla is no longer completely present and lies apical to the contact point and not at the same level as the adjacent papillae, but the iCEJ is still not visible.

PPI 3(Papilla Presence Index score-3): Papilla is moved more apical and the iCEJ becomes visible.

PPI 4(Papilla Presence Index score-4): Papilla lies apical to both the iCEJ and buccal CEJ.

Nemcovskyhad proposed a classification system as a Papillae Index Score (PIS) based on a comparison with adjacent teeth⁸:

PIS 0 (Papilla Index Score 0): Papilla not present and no curvature of the soft tissue contour.

PIS 1 (Papilla Index Score 1): Present papilla height less than half the height of the papilla in the proximal teeth and a convex curvature of the soft tissue contour.

PIS 2 (Papilla Index Score 2): Presence of at least half the height of the papilla in the proximal teeth, but not in complete harmony with the interdental papilla of the proximal teeth.

PIS 3 (Papilla Index Score 3): Papilla able to fill the interproximal embrasure to the same level as in the proximal teeth and in complete harmony with the adjacent papillae.

MANAGEMENT OF BLACK TRIANGLE

Several surgical approaches using traditional periodontal plastic and augmentation procedures to overcome this problem have been proposed. However, these techniques were found to be challenging as the interdental papilla is a little, friable area with minor blood supply which affects the outcome of all techniques aiming at reconstruction of lost interdental papilla. Non-surgical attempts to treat papillary deficiencies include orthodontic, restorative and prosthodontic approaches. Also, a non-invasive technique with the use of hyaluronic acid (HA) gel has been recently proposed.

NON-SURGICAL APPROACH

1. Correction of traumatic oral hygiene procedure

For treatment of black triangle caused as a result of rigorous brushing, hygiene in that area should be modified; the toothbrush should be change, allowing it for re-epithelialization of injury and can restoration of the papilla.^{9,10}

2. Restorative approach

Composite can be placed in close proximity to gingival sulcus as a template for the formation of an interdental papilla⁸. The benefits of composite is that it has many colors that are stable and wear resistant; the recently introduced dental bonding agents permits the bonding of composites to dentine. The demerits are that there may be change in color, fluid percolation via the dental interface and composite. Kim and Cho closed diastema using direct composite resin and modified Mylar strip technique.¹¹

The drawback of this technique was that any incorrect resin composition can result in wear, fracture and limited success rate. Another method is ceramic veneer or crown. Adding pink ceramic to the restoration can handle the presence of interdental papilla deficiency⁹. The benefits of this technique are biological compatibility of the material, stable color and non-porous surface, hampering better accumulation of local factors than composite resins. The demerits are technique sensitive and difficult to fix¹⁰.

3. Orthodontic approach

Bodily movement of the two adjacent teeth can lead to orthodontic closure of interdental space. This is done to reduce the interdental space to create a contact point between the adjacent teeth and to build up the lost papilla. Along with orthodontic therapy, interproximal reduction of enamel is one of the methods to achieve contact point. Interproximal diminishing of enamel on triangular crown will modify contact point to a broader contact area thereby decreasing black triangle. Normally 0.5-0.75mm enamel can be reduced to prevent occurrence of open embrasures. Livas in one of his studies showed that a maximum of 50% of interproximal enamel can be reduced without any dental risk.¹²

Divergent roots also lead to black triangle space. Reduction of black triangle area is done by placing more contact points into the apical region.⁹

4. Prosthetic approach

Gingival prosthesis can be used to treat interdental papillary deficiency. Removable acrylic or silicone can be utilised as a gingival veneer to mask lost gingival tissues and is indicated in interdental defect with a space in between the contact point and alveolar crest >5 mm and in patients who cannot afford to undergo consecutive surgical procedures. Contraindications are patients with compromised periodontal health, poor oral hygiene, patients who are at risk of caries. Materials that can be used are: Auto and heat polymerizing acrylic resin, rigid, flexible material, copolyamide, soft silicone material.¹⁰

5. Repeated curettage

Shaipiro in his study showed that repeated curettage after every 15 days for 3 months to create papillae degenerated by necrotizing gingivitis, induces a proliferative hyperplastic inflammatory response of the papilla.¹³ After 9 months of initial treatment, regeneration of interdental papillae was seen. The results were variable with complete regeneration to no response. Yanagishita¹⁴ et al. analysed improvement of interdental papilla in a patient undergoing maintenance therapy. All the recruited patients for the study were asked to discontinue the usage of proximal brush to allow for the recovery of interdental papillae. A consistent improvement was seen in deficiency of the interdental papilla over a period of several years together with coronal regrowth of the gingival margin.

6. Hyaluronic acid gel

A non-invasive technique with the use of hyaluronic acid (HA) gel filler with prompt results has been recently proposed. HA has an essential role in space-filling due to its hygroscopic nature, hence it helps in regeneration of lost interdental papilla. It also regulates osmotic pressure and enhances tissue lubrication and resiliency, that helps in maintaining the structural and homeostatic integrity of tissues. Limited studies have used HA gels for papillary reconstruction but still lacking a high degree of evidence and certainty. More studies are needed to evaluate the use of injectable HA-based gels as a minimally invasive approach for the treatment of interdental papillary loss.

SURGICAL APPROACH

For the success of surgical treatment thick gingival biotype is required. The interdental papilla is a friable area with a minor blood supply. This is the main limiting factor in surgical reconstructive and augmentation techniques for the management of Black triangle.

Surgical approaches include:

1. Papilla re-contouring.

2. Papilla preservation.
3. Papilla reconstruction.

Papilla re-contouring: In the case of gingival enlargement, gingivectomy is done to remodel the soft tissue architecture.

Papilla preservation: Various surgical techniques to recreate and preserve the interdental papilla have been introduced.

1. Conventional papilla preservation flap

Takei et al. in 1985 had introduced conventional papilla preservation technique¹⁵. Around concerned tooth sulcular incisions are given and a semilunar incision is made across each interdental papilla with the lingual/palatal flap at roughly 5 millimetre from the margin of gingiva permitting the interdental tissues to be reflected from the lingual/palatal aspect so that it can be elevated completely with facial flap.

2. Modified papilla preservation flap

Cortellini et al. (1995) gave a new modification of conventional papilla preservation technique.¹⁶ and is a Minimally Invasive Surgical Technique. On the buccal side at the bottom of the papilla horizontal incision is given. The papilla is reflected toward the palatal side. It is usually recommended for thick interdental papilla in broad interdental spaces.

3. Simplified papilla preservation flap

Simplified papilla preservation technique is recommended for narrow interdental spaces (≤ 2 mm). It is a modification of Cortellini's Modified papilla preservation.¹⁷ An oblique incision is given on the buccal aspect and bottom of the interdental papilla, and then reflection of papilla towards the palatal aspect is done. An oblique incision is given along the defective papilla from the margin of gingiva at the buccal line angle of the concerned tooth to reach the mid interproximal portion of the papilla of the neighbouring tooth. Thereafter it is extended intrasulcularly in the buccal aspect of the teeth nearby the defect and carried to partially dissect the papillae of the adjacent interdental spaces so that buccal flap can be elevated with 2-3mm exposure of alveolar bone.

4. The "Whale's tail" technique

Bianchi and Bassetti in 2009 introduced a technique known as Whale's tail technique.¹⁸ It preserves the interdental tissue by guided tissue regeneration and is indicated for the treating intrabony defects in the esthetic zone. The Reflection of a flap from the buccal to the palatal side permitting accessibility and visualisation of the intrabony defect and placement of the membrane while maintaining interdental tissue over grafting material. The reflected flap gives appearance of tail of a whale, hence the name Whales Tail technique.

Papilla reconstruction: Various methods have been proposed to reconstruct the interdental tissues.

1. Pedicle flap

This technique basically combines the Abrams roll technique and Evian papilla preservation technique^{19,20}. In region of deficient interproximal papilla, a palatal split-thickness flap is elevated and reflected buccally. The flap is rolled on itself and sutured to make the new papilla it is sutured in between the two incisors.

2. Semilunar coronally repositioned flap

Tarnow²¹ has introduced this treatment modality.

The modification was that semilunar incision was given in the interproximal region. Intrasulcular incisions are also placed around the mesial and distal half of the two neighbouring teeth to free the connective tissue from the radicular surfaces and permitting the displacement of gingivo-papillary unit

in coronal direction. After that epithelial connective tissue obtained from the palate is placed in the semilunar incision and into the pouch .

3. Envelop type flap

intrasulcular and buccal incision are made across the interdental papilla that needs to be regenerated and are at the level of cemento-enamel junction. An envelope type split thickness flap is reflected buccally and palatal split thickness flap is reflected buccally beyond the mucogingival line., . A connective tissue graft of required dimensions placed under the flaps in recipient site.²²

4. Autogenous osseous and connective tissue grafts

In this technique intrasulcular incision is placed on the labial and palatal aspects of the lateral and central incisors conserving as much gingiva as possible. A horizontal incision from the mucogingival junction, reaching in to the alveolar mucosa and apically extending to the labial vestibular fold, is placed to elevate a split-thickness flap. coronal displacement of entire gingiva-papillary unit is done.. Bone graft obtained from the maxillary tuberosity is reframed to form a saddle to fit over the interdental crest and stabilized with a titanium screw. Crushed cancellous bone is packed around the grafted bone . From the palate, a connective tissue graft is obtained and is placed on top of the bone graft to cover the complete augmented area.²³

5. Microsurgery

Available data documents a case report of three cases describing the microsurgical technique for management of deficient Interdental Papilla. Surgery is done without using releasing incisions. Thus it increases the chances of donor tissue survival and cause minimal tissue trauma, excessive bleeding, and pain. As, the blood supply remains intact, donor tissue survival is optimized.²⁴

CONCLUSION

Black triangle leads to various functional and esthetic problems and influences the pattern of smile too. If the amount of interdental papillary loss is minimal with adequate periodontal health, non surgical methods are indicated. . Surgical procedures are recommended in case of comparatively more interdental papillary loss and dense gingival biotype. Selected surgical technique should be able to maintain sufficient vascular supply from the flap to the graft material, thus maintaining integrity of the interdental papilla and preventing flap necrosis..

Various studies are quoted in literature for management of black triangles and had shown good clinical results but the predictability of various procedures has not been completely documented. Further follow up research is required to predict the long term stability of various procedures.

REFERENCES

1. Cunliffe J, Pretty I. Patient's ranking of interdental "black triangles" against other common aesthetic problems. *Eur J Prosthodont Restor Dent.* 2009;17(4):177-181.
2. Prato GP, Rotundo R, Cortellini P, Tinti C, Azzi R. Interdental papilla management: A review and classification of the therapeutic approaches. *Int J Periodont Rest Dent.* 2004;24:246-55.
3. Cohen B. Morphological Factors in the pathogenesis of the periodontal disease. *Br Dent J.* 1959;107:31-9.
4. Lee W, Kim H, Yu S, Kim B. Six Month Clinical Evaluation of Interdental Papilla Reconstruction with Injectable Hyaluronic Acid Gel Using an Image Analysis System. *J Esthet Resto Dent.* 2016;28(3):221-230.
5. Zetu L, Wang HL. Management of inter-dental/interimplant papilla. *J Clin Periodontol.* 2005; 32(7): 831-39.
6. Nordland WP, Tarnow DP. A classification system for loss of papillary height. *J Periodontol.* 1998;69(10):1124-6.
7. Cardaropoli D, Re S, Corrente G. The Papilla Presence Index (PPI): A new system to assess interproximal papillary levels. *Int J Periodontics Restorative Dent.* 2004;24(5):488-92.
8. C Nemcovsky. Interproximal Papilla Augmentation Procedure: A Novel Surgical Approach And Clinical Evaluation Of 10 Consecutive Procedures. *Int J Periodontics Restorative Dent.* 2001; 21(6): 553-559.
9. J.D.D. Olivira, C.M. Storrer, A.M. Sousa, T.R. Lopes, J.D.S. Vieira, T.M. Deliberado, Papillary regeneration: anatomical aspects and treatment approaches *RSBO(Online)* 2012;9(4): 448- 56.

10. Y. Ravishankar, K. Srinivas, S.K. Sharma, S.P. Kumar. Management of black triangles and gingival recession: a prosthetic approach. *Indian J. Dent. Sci.* 2012;4(1): 141-145 .
11. Y.H. Kim And Y.B. Cho, Diastema Closure With Direct Composite: Architectural Gingival Contouring, *J of Korean Acad Conserv Dent.* 2011; 36(6): 515–520,
12. D. C. Livas, Enamel Reduction Techniques In Orthodontics: A Literature Review, *Open Dent. J.* 2013; 7(1), 146–151.
13. Shapiro A. Regeneration of interdental papillae using periodic curettage. *Int J Periodont Rest Dent.* 1985;5(5):27-33.
14. Y. Yanagishita, K. Yoshino, Y. Taniguchi, Y. Yoda, And T. Matsukubo, Nonsurgical Recovery Of Interdental Papillae Under Supportive Periodontal Therapy. *Bull Tokyo Dent. Coll.* 2012; 53(3): 141–146
15. Takei HH, Han TJ, Carranza FA Jr, Kenney EB, Lekovic V. Flap technique for periodontal bone implants. Papilla preservation technique. *J. Periodontol.* 1985; 56(4): 204-10.
16. Cortellini P, Prato GP, Tonetti MS. The modified papilla preservation technique. A new surgical approach for interproximal regenerative procedures. *J. Periodontol.* 1995; 66(4):261-6.
17. Cortellini P, Prato GP, Tonetti MS. The simplified papilla preservation flap. A novel surgical approach for the management of soft tissues in regenerative procedures. *International Journal Periodontics Restorative Dentistry* 1999;19: 589-99.
18. Bianchi AE, Bassetti A. Flap design for guided tissue regeneration surgery in the esthetic zone: The “Whale’s tail” technique. *Int J Periodontics Restorative Dentistry* 2009; 29:153-9.
19. Abrams L. Augmentation of the deformed residual edentulous ridge for fixed prosthesis. *Compend Contin Educ Gen Dent* 1980;1:205-14.
20. Evian CI, Corn H, Rosenberg ES. Retained interdental papilla procedure for maintaining anterior esthetics. *Compend Contin Educ Dent* 1985;6:58-64.
21. Tarnow DP. Semilunar coronally repositioned flap. *J Clin Periodontol* 1986;13:182-85.
22. Azzi R, Etienne D, Carranza F. Surgical reconstruction of the interdental papilla. *Int J Periodontics Restorative Dent* 1998;18:467-74.
23. Azzi R, Takei HH, Etienne D, Carranza FA. Root coverage and papilla reconstruction using autogenous osseous and connective tissue grafts. *Int J Periodontics Restorative Dent* 2001;21:141-7.
24. Nordland WP, Sandhu HS, Perio C. Microsurgical technique for augmentation of the interdental papilla: Three case reports. *Int J Periodontics Restorative Dent* 2008;28:543-9.