

# COMPARISON OF MAXILLARY AND MANDIBULAR ARCH FORM IN CLASS I, CLASS II AND CLASS III PATIENTS REPORTING FOR TREATMENT.

<sup>1</sup>Inchara. R, <sup>2</sup>A.Sumathi Felicita, <sup>3</sup>Arya S Prasad\*

<sup>1</sup>Saveetha Dental College and Hospitals Saveetha Institute of Medical and Technical Sciences Saveetha University  
Chennai.

<sup>2</sup>Professor Department of Orthodontics Saveetha Dental College and Hospitals Saveetha Institute of Medical and Technical Sciences Saveetha  
University  
Chennai.

<sup>3</sup>\*Assistant Professor, Department of Orthodontics Saveetha Dental College and Hospitals Saveetha Institute of Medical and Technical Sciences  
Saveetha University Chennai.

DOI: 10.47750/pnr.2022.13.S06.351

## Abstract

**Background:** - Archforms play an important role in orthodontic diagnosis and treatment planning. Limitations for tooth movement, especially for incisor retraction arise from the basal bone where teeth are rooted. If teeth move excessively over the alveolar bone, periodontal complications and unstable treatment effects, even the tooth exfoliation may occur. The aim of this study is to compare the maxillary and mandibular arch forms of class I, class II, class III patients reporting for treatment in Saveetha dental college and hospitals, Chennai, Tamil nadu from June 2019 to January 2021.

**Materials and method:** - It is a single centered retrospective study conducted in a private dental institution, Chennai. The data of patients reporting was collected from the dental hospital management system and the arch form was compared. Ethical clearance for this study was obtained from the Institutional review board. Statistical analysis was obtained using SPSS version 20.

**Results:**-The results showed that there is no significant correlation in maxillary and mandibular arch forms among Angle's Class I, Class II, and Class III malocclusion. Class I occlusal relationship was the most common class of malocclusion followed by Class II malocclusion. Ovoid arch was more common in class I, Class II, Class III malocclusion.

**Conclusion:** - Within the study limits, it was concluded that Class I occlusal relationship was the most common class of malocclusion followed by Class II. Ovoid arch was more common in class I, Class II, Class III malocclusion followed by v-shaped and square arch forms in class I and class III and V-shaped arch was more prominent in class II patients.

**Key words:** Arch form; class I malocclusion; class II malocclusion; class III malocclusion; innovative technology; novel method.

## Introduction

The dental arch form evaluation has become an important part of orthodontic treatment planning. It is well known that a change in intercanine width, during orthodontic therapy, may represent a predictor of dental relapse and, for these reasons, it is fundamental to maintain the original arch dimension by choosing the right arch wire form during the treatment.(1) Moreover, a diversity of dental arch shapes and dimensions in different ethnic groups was observed and several authors proposed geometric models in order to identify the mean configuration of the clinical arch shapes in different populations.(2)

It has been recognized that Angle's classes of malocclusion show a high variability in the shape and size of arch form. Dental arch form is a reflection of the underlying bone morphology.(3) Stability of arch form is one of the most desirable goals of orthodontics, yet unfortunately it is the least understood goal. Arch form tends to return to its original form so the patient's existing arch form appears to be the best guide to the future arch form and stability.(4) Previous

knowledge suggests that a correlation exists between craniofacial structures, arch forms and dimensions. However, the strength of associations is not clearly reported in the literature. Individual variations are also not uncommon.(5) Most of the studies conducted on arch form are focused on finding a single shape in perfect conformity for the dental arch of a specific sample.(6) Despite individual differences, when the ethical variations are taken into consideration; the application of a single ideal arch form for every individual could affect the post treatment functional, esthetic and stable arch form outcomes(7).

Among the various types of malocclusion found in human population Angle's class III malocclusion is one of the least common malocclusions seen in day to day practice.(8) Even though the prevalence of class III is extremely low, the treatment planning for class III seems to be a great challenge for dentists.(8,9) Class III malocclusion is found in 0 to 26.7% in different populations. In class III malocclusion, there is an anteroposterior discrepancy between the maxillary and mandibular dentitions which may or may not be accompanied with skeletal discrepancy.(10) The treatment aspect of class III malocclusion focuses on the correction of skeletal discrepancy, dentoalveolar compensation, reducing reverse overjet and arch forms to name a few.(11)

The arch form before the start of treatment is fundamental in orthodontic treatment planning. The pretreatment arch form is adjusted to the skeletal base and soft tissues which might be determined by genetic and environmental factors. All the changes during pretreatment should be assessed before amending the arch form during treatment to determine potential instability and quantized. Therefore, the aim of the current study is to compare maxillary and mandibular arch forms in class I, class II and class III patients reporting for treatment in Saveetha dental college and hospitals. Our team has extensive knowledge and research experience that has translate into high quality publications(12),(13),(14),(15),(16),(17),(18),(19),(20),(21),(22),(23) ,(24–28) (29),(30),(31)

## Materials and Method

It is a single centered retrospective study conducted in a private dental institution, in Chennai. The data was collected from the dental hospital management system. Ethical clearance for this study was obtained from the Institutional review board.

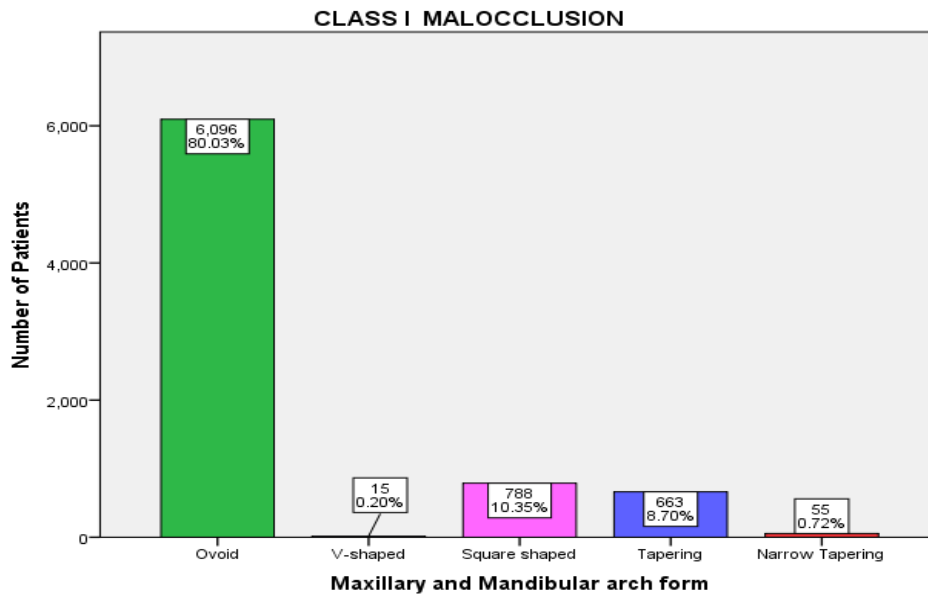
The data included a varied population predominantly South Indian population. All the details of the patients from June 2019 to January 2021 were collected. Total of 8168 patient details were obtained out of which 7618 patients had class I malocclusion, 442 patients with class II malocclusion, and 96 patients with class III malocclusion. All data were cross verified by another examiner. The internal validity included cases diagnosed as per selection criteria, medical history, chief complaints and clinical findings. Inclusion criteria include patients above the age of 18 years and patients who reported for orthodontic treatment. Exclusion criteria include presence of systemic disorders and pediatric patients.

The data collected was tabulated under following parameters : Age, gender, structural abnormalities. The arch form was determined by using photographs from the patient record management system. The independent variable includes age and dependent variables include dental malocclusion and arch form. The data analysis was performed using SPSS software of version 21. The chi square test was used to compare the data and check for the distribution at 0.05 level of significance for effect of statistical significance.

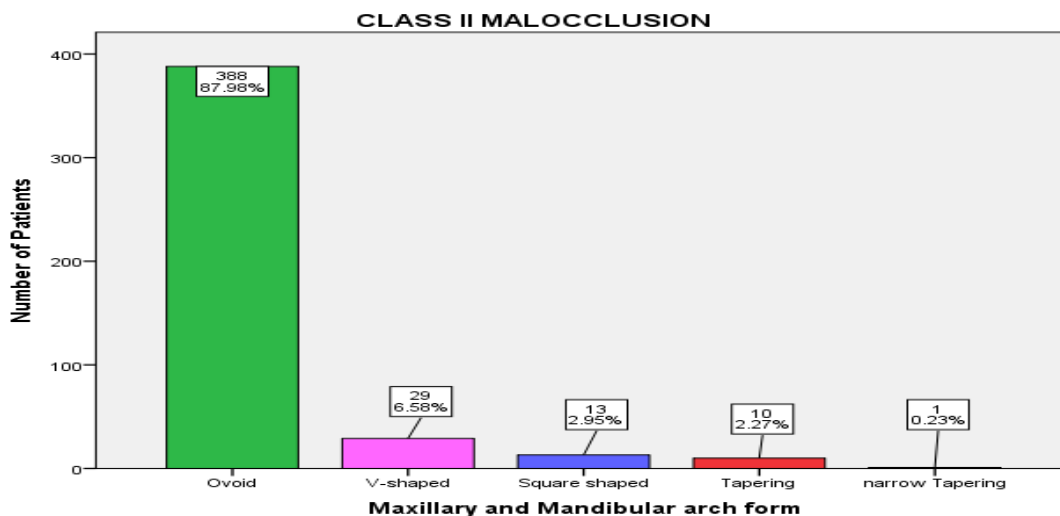
## Results and Discussion

In this study the results show that ovoid arch is more prominent in all Class I, Class II and Class III malocclusion. Figure 1 shows arch shape in class I malocclusion patients. Maxillary and mandibular arch forms were determined together. Out of the 7605 patients with class I malocclusion, 6097 patients (80.04%) had ovoid arch form, 15 patients (0.20%) had v-shaped arch, 788 patients(10.35%) had square shaped arch, 653 patients(8.57%) had tapered, 49 patients( 0.64%) had narrow tapering arch referring to the Ricketts pentamorphic arch for templates.(32). Figure 2 shows arch shape in class II malocclusion patients. Out of 442 patients 388 patients(87.98%) had U-Shaped arch, 29

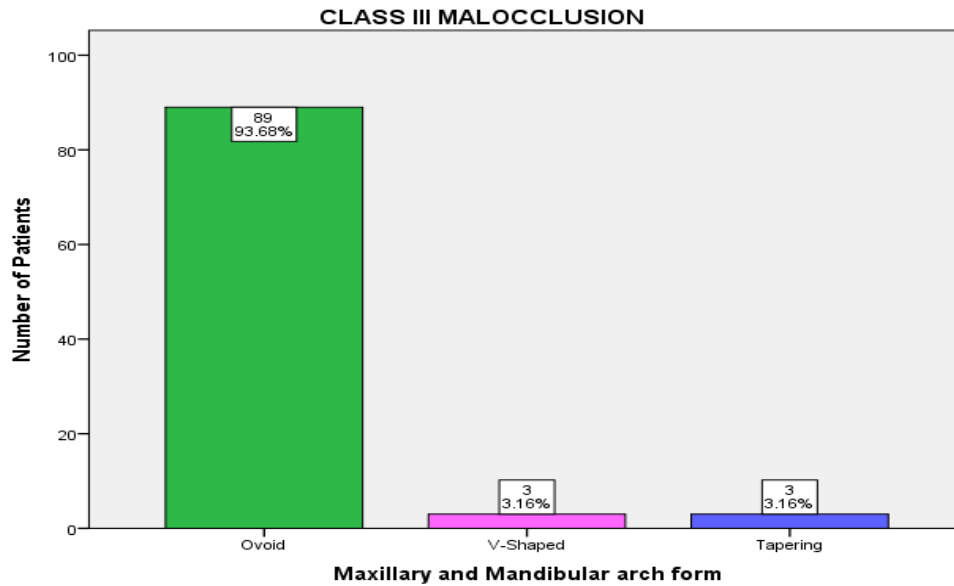
patients(6.58%) had V-Shaped arch, 13 patients( 2.95%) had square shaped arch, 10 patients (2.27%) had oval shaped arch, 1 patient(0.23%) had tapering arch. Figure 3 shows arch shape in class III patients. Out of 96 patients, 89 patients (93.68%) had U-shaped arch, 3 patients(3.16%) had V- shaped arch, 3 patients(3.16%) had oval shaped arch. There was no significant correlation in maxillary and mandibular arch shape among malocclusion of Angle Class I, Class II, and Class III (Figure 4)(Table 1).



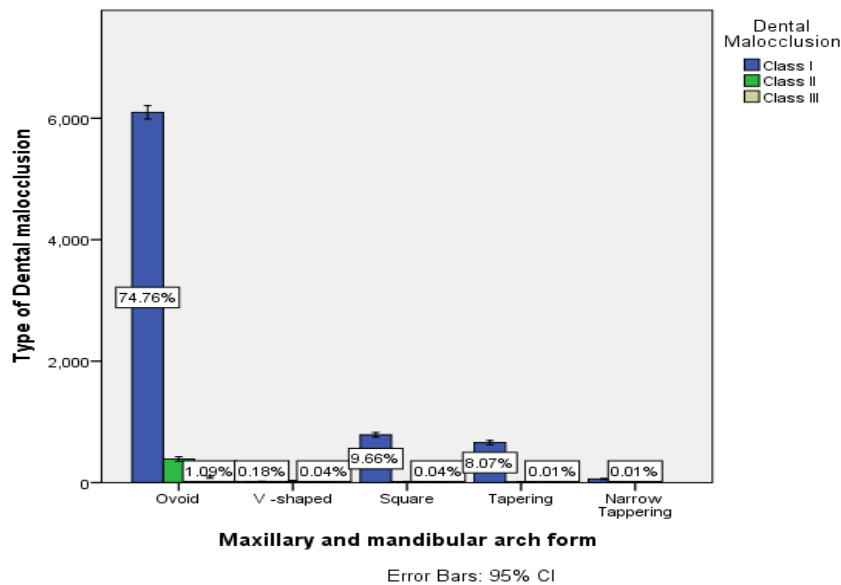
**Figure 1** - Represents arch shape in patients with class I malocclusion patients. The x-axis represents arch shape and the y-axis represents the number of patients. Green colour represents ‘Ovoid’(80.04%) arch, pink colour represents V-Shaped (0.20%) arch, blue colour represents ‘Square shaped’(10.35%), red colour represents ‘Tapering’(8.57%) arch, light blue represents ‘Narrow tapering’(0.64%),



**Figure 2** - Represents arch shape in patients with class II malocclusion patients. The x-axis represents arch shape and the y-axis represents the number of patients. Green colour represents ‘Ovoid’(87.98%) arch, pink colour represents V-Shaped (6.58%) arch, blue colour represents ‘Square shaped’(2.95%) arch, red colour represents ‘Tapering’(2.27%) arch, light blue represents ‘Narrow tapering’(0.23%) arch.



**Figure 3** - Represents arch shape in patients with class II malocclusion patients. The x-axis represents arch shape and the y-axis represents the number of patients. Green colour represents 'Ovoid'(93.68%) arch, pink colour represents V-Shaped (3.16%)arch, blue colour represents 'tapering'(3.16%) arch.



**Figure 4** - Represents arch shape in patients with Dental malocclusion patients. The x-axis represents arch shape and the y-axis represents the number of patients. Blue colour represents class I malocclusion, green colour represents class II malocclusion and light brown represents class III malocclusion.

DENTAL MALOCCLUSIO N	ARCH FORM					TOTAL
	Ovoid	V-shaped	Square	tapering	Narrow Tapering	
CLASS I	6097	15	788	653	49	7602

CLASS II	388	29	13	11	1	442
CLASS III	89	3	3	1	0	96
TOTAL	6574	47	804	665	50	8155
P-VALUE	0.000					

Table 1 - Frequency of Number of patients and arch form.

Previous studies that compared arch forms in adult subjects having Angle's Class I normal occlusions and Class III malocclusions have left unanswered questions. The results in this study showed that U- shaped arches were the most common among the Angle's classification groups namely, class I malocclusion (80.04%) (Figure 1), class II malocclusion (87.98%)(Figure 2) and class III malocclusion (93.68%)(Figure 3). In the study conducted by Raghda Al-Shammout et al. When comparing the arch form (square, tapered and ovoid) according the different classes, the most common arch form in Class I was the ovoid, tapered in Class II and square in Class III subjects.(33). According to the study by Sultan Olmez et al, there was no significant difference with respect to arch form between Class I and Class II arches. Tapered arch form was seen in high frequency in both groups whereas the sequence of ovoid arch form was less. (34)

Consideration of the arch form is of utmost importance, because it is imperative that arch form should be examined before embarking upon the treatment as this gives valuable information about the position into which teeth can be moved if they are to be stable following treatment , and moreover, the arch form needs to be preserved as this would contribute to the stability of the orthodontic treatment that would have to be done and prevent relapse.(33,35) With the availability of different preformed shapes and sizes of arch wires, different studies have highlighted the importance of selection of patient's clinical arch form and customization of arch form.(36)Limitation of the study is that it is a single centered study with small population and therefore, the present study may serve as population study and a database for future comparisons and to obtain baseline information on the morphological arch dimensions of the fully dentate population since these variations highly influence orthodontic and prosthetic rehabilitation of patients.

## Conclusion

Within the study limits, it was concluded that Class I occlusal relationship was the most common class of malocclusion followed by Class II. ovoid arch was more common in class I, Class II, Class III malocclusion followed by v-shaped and square arch forms in class I and class III and V-shaped arch was more prominent in class II patients.

## Conflict of interest

No

## Acknowledgement

We would like to thank all the participants who took part in the study. We also thank Saveetha dental college and hospitals for their constant help and support.

## AUTHOR CONTRIBUTION

The first author (Inchara.R) performed literature search, data collection, analysis , manuscript writing. The second author (Dr. A Sumathi Felicita) contributed study design , data verification and revision of the manuscript. The third author (Dr Arya S Prasad) contributed in manuscript writing and follow up.

## SOURCE OF FUNDING:-

The present project is funded by

- Saveetha Institute of Medical and Technical Sciences.

- Saveetha Dental college and Hospitals.
- Saveetha University.
- Rakshith homes pvt.ltd.

## REFERENCE

1. Mehta N, Patel D, Mehta F, Patel N, Trivedi I, Mehta A. Evaluation of arch width among Class I normal occlusion, Class II Division 1, Class II Division 2, and Class III malocclusion in Indian population [Internet]. Vol. 6, Contemporary Clinical Dentistry. 2015. p. 202. Available from: <http://dx.doi.org/10.4103/0976-237x.166842>
2. Wermerson CP. Comparison of tooth widths, arch widths, arch lengths in early mixed and permanent class I normal dentitions to class I and II crowded dentitions [Internet]. Available from: <http://dx.doi.org/10.17077/etd.ph5roqw8>
3. Table 6: Difference in facial indices between sagittal malocclusions (Class I, Class II, and Class III) [Internet]. Available from: <http://dx.doi.org/10.7717/peerj.6889/table-6>
4. VanLaecken R. Class III correction using an inter-arch spring loaded module [Internet]. Available from: <http://dx.doi.org/10.33915/etd.3439>
5. Buyukcavus MH, Kale B, Aydemir B. Comparison of treatment effects of different maxillary protraction methods in skeletal class III patients [Internet]. Vol. 23, Orthodontics & Craniofacial Research. 2020. p. 445–54. Available from: <http://dx.doi.org/10.1111/ocr.12389>
6. Filho CMC, Coelho FO. The Mandibular Protraction Appliance in the treatment of noncompliant Class II patients [Internet]. Orthodontic Treatment of the Class II Noncompliant Patient. 2006. p. 93–105. Available from: <http://dx.doi.org/10.1016/b978-0-7234-3391-0.50012-4>
7. Kamoltham K, Charoemratrote C. Treatment effects of mandibular anterior position training versus a fixed Class II corrector in growing patients with skeletal Class II malocclusion [Internet]. Vol. 77, Orthodontic Waves. 2018. p. 209–19. Available from: <http://dx.doi.org/10.1016/j.odw.2018.07.003>
8. Azamian Z, Shirban F. Treatment Options for Class III Malocclusion in Growing Patients with Emphasis on Maxillary Protraction [Internet]. Vol. 2016, Scientifica. 2016. p. 1–9. Available from: <http://dx.doi.org/10.1155/2016/8105163>
9. Cosgarea R. Treatment of multiple adjacent mandibular Miller Class I and II recessions with the modified tunnel technique [Internet]. Available from: <http://dx.doi.org/10.26226/morressier.5ac383292afeeb00097a4677>
10. Class III Facial Asymmetry, Mandibular Deviation and Its Related Surgical Orthodontic Treatment [Internet]. Orthodontic Treatment of Class III Malocclusion. 2014. p. 228–58. Available from: <http://dx.doi.org/10.2174/9781608054916114010012>
11. Ngan PW, Deguchi T, Roberts EW. Orthodontic Treatment of Class III Malocclusion. Bentham Science Publishers; 2014. 478 p.
12. Felicita AS. Orthodontic extrusion of Ellis Class VIII fracture of maxillary lateral incisor - The sling shot method. Saudi Dent J. 2018 Jul;30(3):265–9.
13. Chandrasekar R, Chandrasekhar S, Sundari KKS, Ravi P. Development and validation of a formula for objective assessment of cervical vertebral bone age. Prog Orthod. 2020 Oct 12;21(1):38.
14. Arvind P TR, Jain RK. Skeletally anchored forus fatigue resistant device for correction of Class II malocclusions-A systematic review and meta-analysis. Orthod Craniofac Res. 2021 Feb;24(1):52–61.
15. Khan A, Verpoort F, Asiri AM, Hoque ME, Bilgrami AL, Azam M, et al. Metal-Organic Frameworks for Chemical Reactions: From Organic Transformations to Energy Applications. Elsevier; 2021. 500 p.
16. Alam MK, Alfawzan AA, Haque S, Mok PL, Marya A, Venugopal A, et al. Sagittal Jaw Relationship of Different Types of Cleft and Non-cleft Individuals. Front Pediatr. 2021 May 5;9:651951.
17. Marya A, Venugopal A. The Use of Technology in the Management of Orthodontic Treatment-Related Pain. Pain Res Manag. 2021 Mar 9;2021:5512031.
18. Adel S, Zaher A, El Harouni N, Venugopal A, Premjani P, Vaid N. Robotic Applications in Orthodontics: Changing the Face of Contemporary Clinical Care. Biomed Res Int. 2021 Jun 16;2021:9954615.
19. Sivakumar A, Nalabothu P, Thanh HN, Antonarakis GS. A Comparison of Craniofacial Characteristics between Two Different Adult Populations with Class II Malocclusion-A Cross-Sectional Retrospective Study. Biology [Internet]. 2021 May 14;10(5). Available from: <http://dx.doi.org/10.3390/biology10050438>
20. Venugopal A, Vaid N, Bowman SJ. Outstanding, yet redundant? After all, you may be another Choluteca Bridge! Semin Orthod. 2021 Mar 1;27(1):53–6.
21. Gopalakrishnan U, Felicita AS, Mahendra L, Kanji MA, Varadarajan S, Raj AT, et al. Assessing the Potential Association Between Microbes and Corrosion of Intra-Oral Metallic Alloy-Based Dental Appliances Through a Systematic Review of the Literature. Frontiers in Bioengineering and Biotechnology. 2021;9:154.
22. Venugopal A, Vaid N, Bowman SJ. The quagmire of collegiality vs competitiveness. Am J Orthod Dentofacial Orthop. 2021 May;159(5):553–5.
23. Marya A, Karobari MI, Selvaraj S, Adil AH, Assiry AA, Rabaan AA, et al. Risk Perception of SARS-CoV-2 Infection and Implementation of Various Protective Measures by Dentists Across Various Countries. Int J Environ Res Public Health [Internet]. 2021 May 29;18(11). Available from: <http://dx.doi.org/10.3390/ijerph18115848>
24. Ramesh A, Varghese S, Jayakumar ND, Malaiappan S. Comparative estimation of sulfiredoxin levels between chronic periodontitis and healthy patients - A case-control study. J Periodontol. 2018 Oct;89(10):1241–8.
25. Arumugam P, George R, Jayaseelan VP. Aberrations of m6A regulators are associated with tumorigenesis and metastasis in head and neck squamous cell carcinoma. Arch Oral Biol. 2021 Feb;122:105030.

26. Joseph B, Prasanth CS. Is photodynamic therapy a viable antiviral weapon against COVID-19 in dentistry? *Oral Surg Oral Med Oral Pathol Oral Radiol.* 2021 Jul;132(1):118–9.
27. Ezhilarasan D, Apoorva VS, Ashok Vardhan N. Syzygium cumini extract induced reactive oxygen species-mediated apoptosis in human oral squamous carcinoma cells. *J Oral Pathol Med.* 2019 Feb;48(2):115–21.
28. Duraisamy R, Krishnan CS, Ramasubramanian H, Sampathkumar J, Mariappan S, Navarasampatti Sivaprakasam A. Compatibility of Nonoriginal Abutments With Implants: Evaluation of Microgap at the Implant-Abutment Interface, With Original and Nonoriginal Abutments. *Implant Dent.* 2019 Jun;28(3):289–95.
29. Gothandam K, Ganesan VS, Ayyasamy T, Ramalingam S. Antioxidant potential of theaflavin ameliorates the activities of key enzymes of glucose metabolism in high fat diet and streptozotocin - induced diabetic rats. *Redox Rep.* 2019 Dec;24(1):41–50.
30. Ezhilarasan D. Hepatotoxic potentials of methotrexate: Understanding the possible toxicological molecular mechanisms. *Toxicology.* 2021 Jun 30;458:152840.
31. Preethi KA, Auxzilia Preethi K, Sekar D. Dietary microRNAs: Current status and perspective in food science [Internet]. Vol. 45, *Journal of Food Biochemistry.* 2021. Available from: <http://dx.doi.org/10.1111/jfbc.13827>
32. Omar H, Alhajrasi M, Felemban N, Hassan A. Dental arch dimensions, form and tooth size ratio among a Saudi sample. *Saudi Med J.* 2018 Jan;39(1):86–91.
33. Shammout RWKA, Al Shammout RWK. The Effect of Various Classes of Malocclusions on the Maxillary Arch Forms and Dimensions in Jordanian Population [Internet]. Vol. 2, *Advances in Dentistry & Oral Health.* 2016. Available from: <http://dx.doi.org/10.19080/adoh.2016.2.555579>
34. Aras I, Olmez S, Akay MC, Gunbay T, Aras A. The effects of maxillary expansion on the soft tissue facial profile. *Istanbul Univ Dishekim Fak Derg.* 2017 Oct 2;51(3):1–10.
35. Malkoc S, Basciftci FA, Nur M, Catalbas B. Maxillary and mandibular mesiodistal tooth sizes among different malocclusions in a sample of the Turkish population [Internet]. Vol. 33, *The European Journal of Orthodontics.* 2011. p. 592–6. Available from: <http://dx.doi.org/10.1093/ejo/cjq111>
36. AlJayousi M, Al-Khateeb SN, Badran S, Alhaija ESJA. Maxillary and mandibular dental arch forms in a Jordanian population with normal occlusion [Internet]. Available from: <http://dx.doi.org/10.21203/rs.3.rs-61067/v1>